

## Case Report

# Rapid Herpes Zoster Infection on Latissimus Dorsi Flap Following Breast Reconstruction: A Case Report

EC Karadag Sari, S Yazar<sup>1</sup>

Department of Plastic, Reconstructive and Aesthetic Surgery, Acibadem Mehmet Ali Aydinlar University, School of Medicine, Acibadem Altunizade Hospital, <sup>1</sup>Plastic, Reconstructive and Aesthetic Surgeon, Private Clinic, Istanbul, Turkey

### Received:

30-Dec-2021;

### Revision:

28-Jan-2022;

### Accepted:

31-Jan-2022;

### Published:

16-Aug-2022

### ABSTRACT

In addition to the esthetic outcomes, autologous breast reconstruction offers satisfactory functional results via sensory recovery of the flap. A herpes zoster infection developed after an autologous breast reconstruction provides objective evidence of spontaneous reinnervation in a reconstructed breast. One previous case of a herpes zoster infection on autologous latissimus dorsi flap has been reported to date; the infection developed 2 years after the breast reconstruction operation. However, our case presents a herpes zoster infection developing only 2 months after surgery. To our knowledge, the present case represents the first reported instance of a herpes zoster infection that developed shortly after the breast reconstruction using a latissimus dorsi flap.

**KEYWORDS:** *Autologous breast reconstruction, herpes zoster infection, latissimus dorsi flap, spontaneous reinnervation*

## INTRODUCTION

Breast reconstruction with autologous tissue provides a natural breast volume and shape. Autologous breast reconstruction provides satisfactory functional results with the sensory recovery of the flap, in addition to the esthetic results. Most of the autologous breast reconstruction studies in the literature analyzed the spontaneous reinnervation of the transverse rectus abdominis musculocutaneous (TRAM) flap. Moreover, these studies' findings were largely subjective, evaluating patients' responses to touch, pain, temperature, and pressure rather than objective signs such as those evident from a herpes zoster infection.<sup>[1-3]</sup> A single case of herpes zoster infection on an autologous latissimus dorsi flap has been reported to date.<sup>[4]</sup> According to that study, a herpes zoster infection developed on the autologous flap 2 years after the breast reconstruction operation.<sup>[4]</sup> Our case presents a herpes zoster infection developing only 2 months after surgery, localized only on the skin paddle

of the flap (i.e., the infection was not present along the right hemithorax and right back). To our knowledge, this is the first case of a herpes zoster infection developing in such a short time following the breast reconstruction using a latissimus dorsi flap.

## CASE


A 40-year-old woman who underwent a right skin-sparing mastectomy for invasive ductal carcinoma followed by radiation therapy presented to our clinic 1 year after her mastectomy. We performed breast reconstruction using a latissimus dorsi flap with an implant. A 300 cm<sup>3</sup>, high profile, textured, round, gel-filled implant was placed

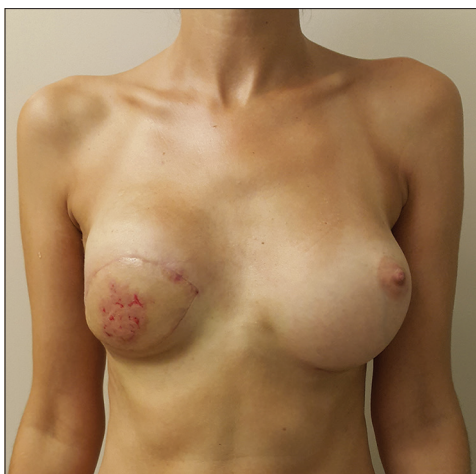**Address for correspondence:** Dr. EC Karadag Sari, Department of Plastic, Reconstructive and Aesthetic Surgery, Acibadem Mehmet Ali Aydinlar University, School of Medicine, Acibadem Altunizade Hospital, Istanbul, Turkey. E-mail: doktorcigdem@yahoo.com

This is an open access journal, and articles are distributed under the terms of the Creative Commons Attribution-NonCommercial-ShareAlike 4.0 License, which allows others to remix, tweak, and build upon the work non-commercially, as long as appropriate credit is given and the new creations are licensed under the identical terms.

**For reprints contact:** WKHLRPMedknow\_reprints@wolterskluwer.com

**How to cite this article:** Karadag Sari EC, Yazar S. Rapid herpes zoster infection on latissimus dorsi flap following breast reconstruction: A case report. *Niger J Clin Pract* 2022;25:1369-71.

Access this article online	
<b>Quick Response Code:</b> 	<b>Website:</b> www.njcponline.com
	<b>DOI:</b> 10.4103/njcp.njcp_2051_21



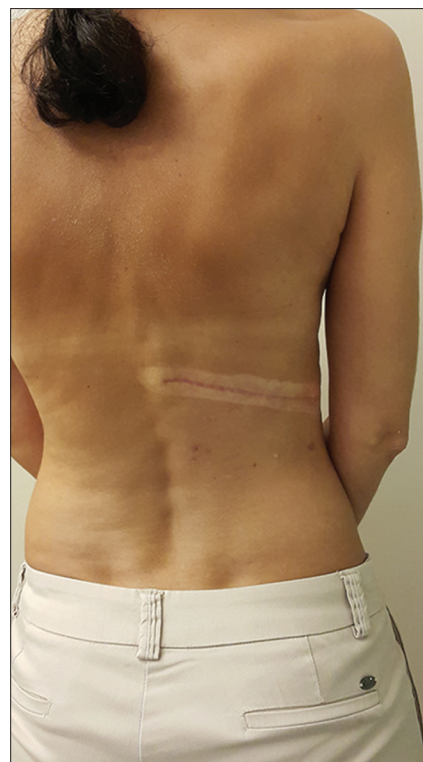**Figure 1:** Erythematous rash with dendritic ulcers on the skin paddle of the latissimus dorsi flap

under the latissimus dorsi and pectoralis major muscles. The patient's postoperative course was uneventful. However, 2 months following the reconstruction, she developed a painful rash on the latissimus dorsi musculocutaneous flap. A physical examination revealed an erythematous rash with dendritic ulcers. As dendritic ulcers were present only on the skin paddle of the latissimus dorsi flap [Figure 1] but not spread along the right hemithorax and right side of the back [Figure 2], our preliminary diagnosis was a circulatory problem in the flap. A change in skin color would help confirm a blood circulation problem; however, 2 days later, no change was noted in the skin color of the flap. Thus, her skin lesions were evaluated by a dermatologist and diagnosed as a herpes zoster infection. The patient was treated with antiviral therapy and all skin lesions healed in 2 weeks without incident. On a routine follow-up visit 2 years after the reconstruction, we noted herpes zoster scars only on the skin of the latissimus dorsi flap [Figure 3].

## DISCUSSION

Autologous breast reconstruction with latissimus dorsi flap yields high patient satisfaction with the esthetic results providing an excellent breast volume and shape. Besides the esthetic outcomes, a return of sensitivity to the reconstructed breast is very important due to the erogenous function of the reconstructed breast.

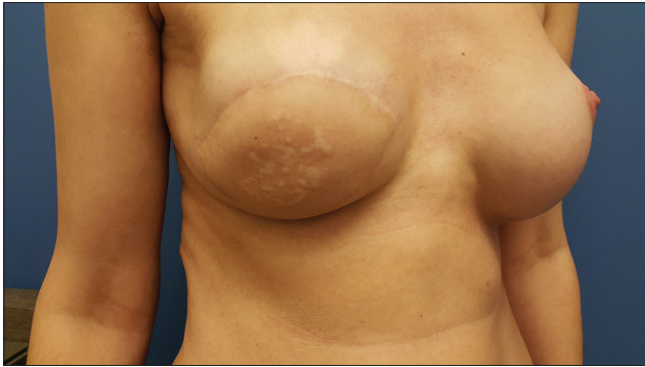Spontaneous reinnervation of a reconstructed breast with autologous flaps is still controversial. Studies have reported that the quality of re-introduced sensory perception depended on the type and the sensory end organs in the transferred flap.<sup>[4]</sup> Similarly, Lehmann *et al.*<sup>[5]</sup> and Shridharani *et al.*<sup>[6]</sup> report the sensation of the transverse rectus abdominal flap was superior compared



**Figure 2:** No herpes zoster eruption on the right hemithorax and right side of the back along with the distribution of the Th5 to Th6 dermatome

with the latissimus dorsi breast reconstruction because the quantity of the end organs was higher in the muscles of the abdominal area compared to those from the back. However, in our study, a herpes zoster infection appeared on the latissimus dorsi flap 2 months after reconstruction—the shortest period for the reinnervation of an autologous flap following breast reconstruction reported in the literature. According to the literature, the shortest recovery of sensation for a pedicled TRAM flap was demonstrated 6 months after breast reconstruction.<sup>[7]</sup>

It is unclear whether reinnervation starts from the skin margins of the flap or the deep surface of the mastectomy bed. Weitgasser *et al.*<sup>[4]</sup> reported a herpes zoster infection of a latissimus dorsi flap 2 years after breast reconstruction. In their study, skin lesions also spread along the Th5 and Th6 dermatome of the right hemithorax. However, in our study, the herpes zoster eruption was only seen on the skin of the latissimus dorsi flap. Weitgasser stated that spontaneous in-growth of the sensory nerves likely started from the skin margin due to the better result of the sensory testing in the outer region of the reconstructed breast. Similarly, we noted spontaneous reinnervation came from the skin margins of the flap rather than the mastectomy bed. Moreover, the appearance of herpes zoster 2 months after breast reconstruction also proved this theory as the presence of the implant between the latissimus



**Figure 3:** Herpes zoster scars on the skin of the latissimus dorsi flap

dorsi musculocutaneous flap and mastectomy bed would prevent reinnervation during such a brief period. However, in contrast to the previous study, the herpes zoster lesions were limited to the latissimus dorsi musculocutaneous flap, and there were no skin lesions around the mastectomy skin flap or the Th5 to Th6 dermatome of the right hemithorax.

Dendritic ulcers appearing on the skin of the autologous flap should raise suspicions for a herpes zoster infection, even a short time after the reconstruction. Our patient's erythematous rash mimicked flap necrosis due to the blisters on the skin. Moreover, there was no dermatomal distribution of these blisters, which would cause suspicions of a herpes zoster infection as a preliminary diagnosis. In the literature, the only differential diagnosis reported was a cutaneous metastasis of the malignancy. However, flap necrosis should also be considered in these circumstances.

A herpes zoster infection of autologous flaps following breast reconstruction is very rare in the literature.

However, such occurrences provide objective proof of reinnervation of the reconstructed tissues. Therefore, autologous breast reconstruction is a favorable option not only due to previously established benefits such as a more natural appearance and re-established sensory perception, but, as proved objectively by the timing of the herpes zoster infection in this patient case, reinnervation happens in a much shorter time compared to what has been previously reported.

### Financial support and sponsorship

Nil.

### Conflicts of interest

There are no conflicts of interest.

### REFERENCES

1. Liew S, Hunt J, Pennington D. Sensory recovery following free TRAM flap breast reconstruction. *Br J Plast Surg* 1996;49:210-3.
2. Shaw WW, Orringer JS, Ko CY, Ratto LL, Mersmann CA. The spontaneous return of sensibility in breasts reconstructed with autologous tissues. *Plast Reconstr Surg* 1997;99:394-9.
3. Santanelli F, Longo B, Angelini M, Laporta R, Paolini G. Prospective computerized analyses of sensibility in breast reconstruction with non-reinnervated DIEP flap. *Plast Reconstr Surg* 2011;127:1790-5.
4. Weitgasser L, Valina SW, Schoeller T, Ehebruster G. Herpes zoster lesions on reconstructed breast skin: Rare objective proof of reinnervation. *Arch Plast Surg* 2017;44:72-5.
5. Lehmann C, Gumener R, Montandon D. Sensibility and cutaneous reinnervation after breast reconstruction with musculocutaneous flaps. *Ann Plast Surg* 1991;26:325-7.
6. Shridharani SM, Magarakis M, Stapleton SM, Basdag B, Seal SM, Rosson GD. Breast sensation after breast reconstruction: A systematic review. *J Reconstr Microsurg* 2010;26:303-10.
7. Yano K, Matsuo Y, Hosokawa K. Breast reconstruction by means of innervated rectus abdominis myocutaneous flap. *Plast Reconstr Surg* 1998;102:1452-60.