

Hamstring autograft and anatomical footprint evaluation for anterior talofibular ligament reconstruction: Cadaveric study

Nazım Karahan¹ , Murat Kaya², Barış Yılmaz³,
Demet Pepele Kurdal³, Elif Nedret Keskinöz⁴
and Esmâ Esin Derin Çiçek⁵

Journal of Orthopaedic Surgery
28(3) 1–6

© The Author(s) 2020

Article reuse guidelines:
sagepub.com/journals-permissions
DOI: 10.1177/2309499020974830
journals.sagepub.com/home/osj



Abstract

Purpose: The aim of the study was to evaluate whether or not there was any incompatibility between two-strand hamstring tendons taken from the same knee and the ATFL and it was the determination of suitable footprint points in the fibula and talus for anatomical ATFL reconstruction. **Methods:** 16 fresh frozen cadaver specimens were dissected to gracilis and semitendinosus tendons and the anterior talofibular ligament. The origins, insertions, distances from osseous landmarks of fibular talus of ATFL were determined. The diameters of gracilis, semitendinosus and ATFL were calculated. There was a moderate correlation between body height and the distance between the distal of inferior lateral malleolus and the fibular adhesion site of ATFL ($r: 36.5$ p: 0.036). There was a weak correlation between body height and the distance between the apex of the lateral talar process and the talus adhesion site of ATFL in a single bundle ($r: 28.4$ p: 0.002). There was no correlation between the distance from proximal and distal adhesion side of ATFL and body height in the double bundle (p: 0.241). **Results:** There was no significant relationship between ATFL diameter and gracilis, semitendinosus and both hamstring in women. A significant relationship at 80.5% was determined between the ATFL and the gracilis diameter in man. A significant relationship at 92.6% was determined between the ATFL and the semitendinosus diameter in man. **Conclusion:** It was determined that there is not compatibility between the gracilis tendons, the semitendinosus tendon and ATFL in women. It should be supported by biomechanical and clinical studies whether this incompatibility has a clinical effect or not.

Keywords

anatomic footprint, anterior talofibular ligament, gracilis, hamstring, semitendinosus

Date received: 20 July 2020; Received revised 15 October 2020; accepted: 28 October 2020

Introduction

Ankle lateral collaterals consist of three ligaments: anterior talofibular ligament (ATFL), calcaneofibular ligament (CFL), posterior talofibular ligament (PTFL). The anatomical location of the ATFL starts from 10 mm proximal to the type of the distal fibula and ends 18 mm below the articular cartilage of the talus.¹ ATFL plays an important role in limiting anterior displacement of the talus and plantar flexion of the ankle thus ATFL provides primary stability in internal rotation and inversion that is the most common mechanism of injury to the ankle ligaments.^{2,3}

¹ Department of Orthopaedics and Traumatology, Corlu State Hospital, Çorlu/Tekirdağ, Turkey

² Department of Orthopaedics and Traumatology, Marmara University, Pendik/Istanbul, Turkey

³ Department of Orthopaedics and Traumatology, Fatih Sultan Mehmet Research and Training Hospital, Ataşehir/Istanbul, Turkey

⁴ Department of Anatomy, Acibadem University, Ataşehir/Istanbul, Turkey

⁵ Department of Radiology, Fatih Sultan Mehmet Research and Training Hospital, Ataşehir/Istanbul, Turkey

Corresponding author:

Nazım Karahan, Department of Orthopaedics and Traumatology, Corlu State Hospital, Zafer, Bülent Ecevit Blv. No:33, 59850 Çorlu/Tekirdağ, Turkey.

Email: nazimkarahan44@gmail.com



Creative Commons Non Commercial CC BY-NC: This article is distributed under the terms of the Creative Commons

Attribution-NonCommercial 4.0 License (<https://creativecommons.org/licenses/by-nc/4.0/>) which permits non-commercial use, reproduction and distribution of the work without further permission provided the original work is attributed as specified on the SAGE and Open Access pages (<https://us.sagepub.com/en-us/nam/open-access-at-sage>).

In ankle sprains, ATFL is affected by 66–85%.^{4,5} Although most of the patients with ATFL injuries were successfully treated with conservative methods such as splinting and rehabilitation. Chronic instability were observed 20% of patients who were not treated correctly in clinical studies.^{6–8} 20–40% of these patients needed surgical intervention.⁹ Surgical methods such as anatomic ligament repair, nonanatomic tenodesis and anatomical ligament reconstruction are used for ATFL rupture.¹ In chronic ankle instability, surgical methods such as nonanatomic tenodesis or anatomic ligament repair are used when primary repair is not sufficient because of defects due to degeneration at ATFL. Although nonanatomic techniques have been successful in patient satisfaction, they are often not preferred because of instability of the subtalar joint, long-term osteoarthritis and limited ankle movements.¹ Therefore, anatomic ligament reconstruction is preferred in chronic ankle instability and in cases where primary repair cannot be performed.

In the literature, gracilis, semitendinosus and patellar tendon are frequently used as grafts for reconstructive surgery in chronic ATFL injury.^{10–12} It has been shown that the thickness and length of hamstring tendons vary according to body mass index, gender and side.¹³ Variations of the starting and ending point in different joints have been shown to have an effect on tendon survival, stability and joint movements in reconstructive surgery.^{14,15} Therefore, evaluating the relationship of these variations with ATFL and the anatomic origin and endpoint for ATFL could have an impact on surgical success.

We had two purposes in this study, first to compare the ATFL and hamstring tendons on the same knee. Second to evaluate appropriate starting points and endpoints for ATFL reconstruction surgery.

Material and method

This anatomical study included 16 nonpaired leg of fresh frozen cadavers which had been stored at +4°C. No leg showed any scar of previous surgery or evidence of clinical deformation in the frontal plane (Table 1). The average conservation time from death to dissection was 1 month. Preoperative ankle roms were measured by goniometer and ankle movements were normal.

Exclusion criteria were: significant osteoarthritis (>Outerbridge grade 3), ligament injury to the medial or lateral ankle, damage hamstring tendons.

Superficial muscle tendons and fascia were carefully removed and exposed the ankle lateral collaterals. The lateral aspect of the ankle was carefully dissected with 2.5 surgical loupes. ATFL starting points and end points were evaluated at the ankle neutral position (plantarflexion/dorsiflexion of 0°). ATFL width was measured using calipers at three sites, a proximal site (fibular attachment), an intermediate site, and a distal site (talar attachment), and the mean values were used.¹⁶ All dissections

Table 1. Descriptive features of cadaveric.

Descriptive Features		
Age (year)	Min–Max (Median)	51–94 (76)
	Ave ± Std	74.07 ± 12.25
Gender, n (%)	Male	10 (62.5)
	Female	6 (37.5)
Side, n (%)	Left	7 (43.75)
	Right	9 (56.25)
BMI	Min–Max (Median)	18–37 (26)
	Ave ± Std	25.38 ± 6.07
Weight (pound)	Min–Max (Median)	92–260 (170)
	Ave ± Std	175.53 ± 54.90
Height (inç)	Min–Max (Median)	60–75 (69)
	Ave ± Std	68.30 ± 5.43

were done by same person because of eliminating inter-observer variability.

Evaluating starting points and end points

The centers of osseous adhesion points of the ATFL in the fibula and the talus were defined. These points were measured between the distal of inferior lateral malleolus and the fibular adhesion site of ATFL and the distance between the apex of the lateral talar process and the talar adhesion site of ATFL. In those with two bundle, this method was measured as proximal bundle and distal bundle.

Hamstring graft preparation

A standard open anteromedial approach of the joint was carried out. Gracilis and semitendinosus tendons were identified at their tibial insertion site and harvested using a closed stripper after a standard release procedure. After the graft was prepared and cleansed from adherent muscle and adipose tissue, the tendon was applied to a 89 newton load for 15 minutes and each tendon diameters were calculated from the surroundings of the double-strand tendons with a digital microcaliper with a resolution of 0.1 mm and an accuracy of 0.02 mm (Neiko 01407A Electronic Digital Caliper, Neiko Tools, China), separately. The thickness was measured at three different points of each specimen and the mean width recorded.^{17–19}

Statistical analysis

The results were analyzed by using IBM SPSS v. 22 (IBM Corp.; Armonk, NY, USA). Descriptive statistical methods (mean, standard deviation, median, frequency, percentage, minimum, maximum) were used to evaluate the study data. The suitability of the quantitative data for normal distribution was tested with the Shapiro-Wilk test. Student T test was used for comparison of two groups of quantitative variables showing normal distribution. Mann Whitney U Test was used for comparison of two groups of quantitative variables that did not show normal distribution. Pearson

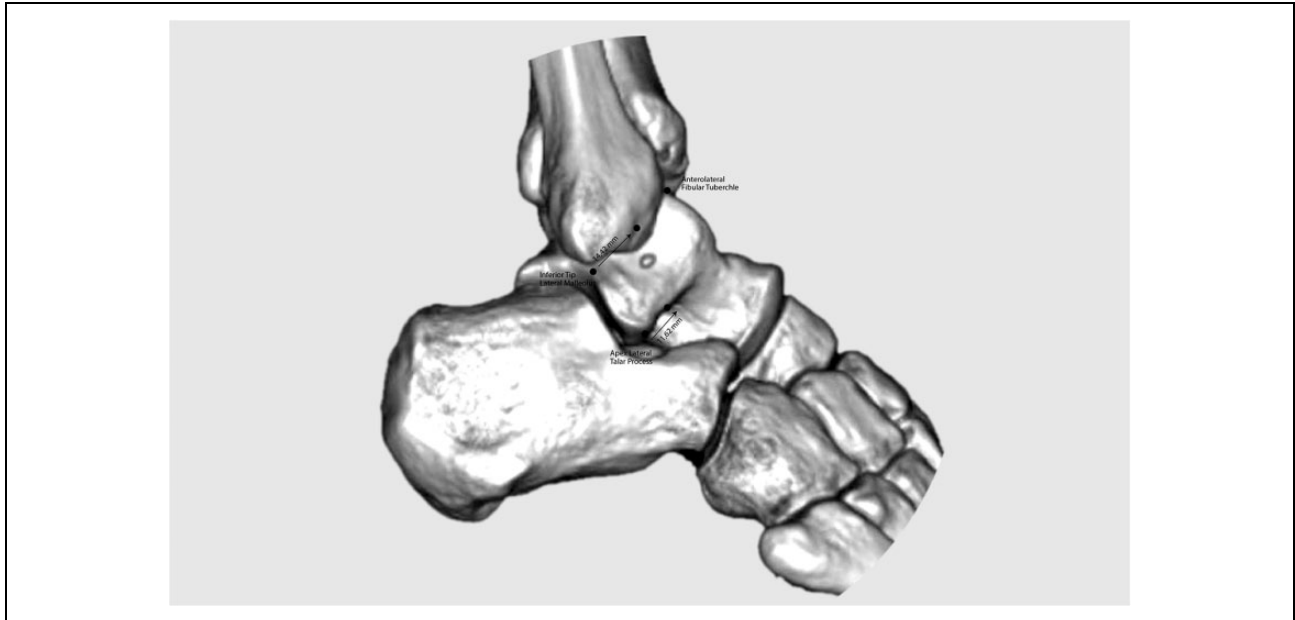


Figure 1. Lateral view of a right ankle in neutral position, showing attachment sites of single bundle of ATFL.

correlation test was used to evaluate the relationships between the parameters. Significance was evaluated at least $p < 0.05$.

Results

In a single bundle, the distance between the distal of inferior lateral malleolus and the fibular adhesion site of ATFL was averaged 14.42 (13.50 to 15.6) mm, the distance between the apex of the lateral talar process and the talus adhesion site of ATFL was averaged 11.62 (10.40 to 12.40) mm (Figure 1). There was a moderate correlation between body height and the distance between the distal of inferior lateral malleolus and the fibular adhesion site of ATFL ($r: 36.5$ $p: 0.036$). There was a weak correlation between body height and the distance between the apex of the lateral talar process and the talus adhesion site of ATFL in a single bundle ($r: 28.4$ $p: 0.002$). There was no statistically significant difference between the distance adhesion side and gender in a single bundle ($p: 0.412$).

In the double bundle, the fibular footprint centers of the superior and inferior bands of ATFL were averaged 16.45 (15.8 to 17.05) mm and 10.73 mm (9 to 12.1) mm, respectively, from the inferior tip of the lateral malleolus at the anterior fibular border. The talar footprint centers of the superior and inferior bands of ATFL were averaged 21.40 (20.5 to 21.90) mm and 11.40 (9.20 to 12.50) mm, respectively, from the apex of the lateral talar process. There was no correlation between the distance from proximal and distal adhesion side of ATFL and body height in the double bundle ($p: 0.241$) There was no statistically significant difference between the distance from proximal and distal

adhesion side of ATFL and gender in the double bundle ($p: 0.16$) (Figure 2).

There was no statistically significant difference between ATFL, gracilis, semitendinosus, and both hamstring (gracilis + semitendinosus) tendon diameters according to descriptive data of cadavery ($p > 0.05$).

There was no significant difference between the number of bundles and gender. Single bundle thickness was 7.29 ± 0.28 mm and double bundle thickness was 7.96 ± 0.55 mm. There was no significant difference between bundle number and gender and height groups ($p > 0.05$). Tendon and ligament diameters according to gender and side are shown in Table 2.

A strong correlation was observed between ATFL diameter and gracilis and semitendinosus diameter (respectively; 80%, 92%). Strong correlation between ATFL diameter and gracilis ($r: 0.79$) and semitendinosus ($r: 0.98$) and both hamstring (gracilis + semitendinosus) ($r: 0.95$) tendons was observed in males. There was no correlation between ATFL diameter and gracilis, semitendinosus and both hamstring (gracilis + semitendinosus) tendon diameters in women (Table 3).

Discussion

The most important findings of the study was a strong correlation between ATFL diameter and gracilis, semitendinosus tendon diameter in men, whereas no correlation was observed between ATFL diameter and gracilis, semitendinosus tendon diameter in females. It was observed that the mean diameter of semitendinosus was closer to the ATFL diameter than the average diameter of gracilis.

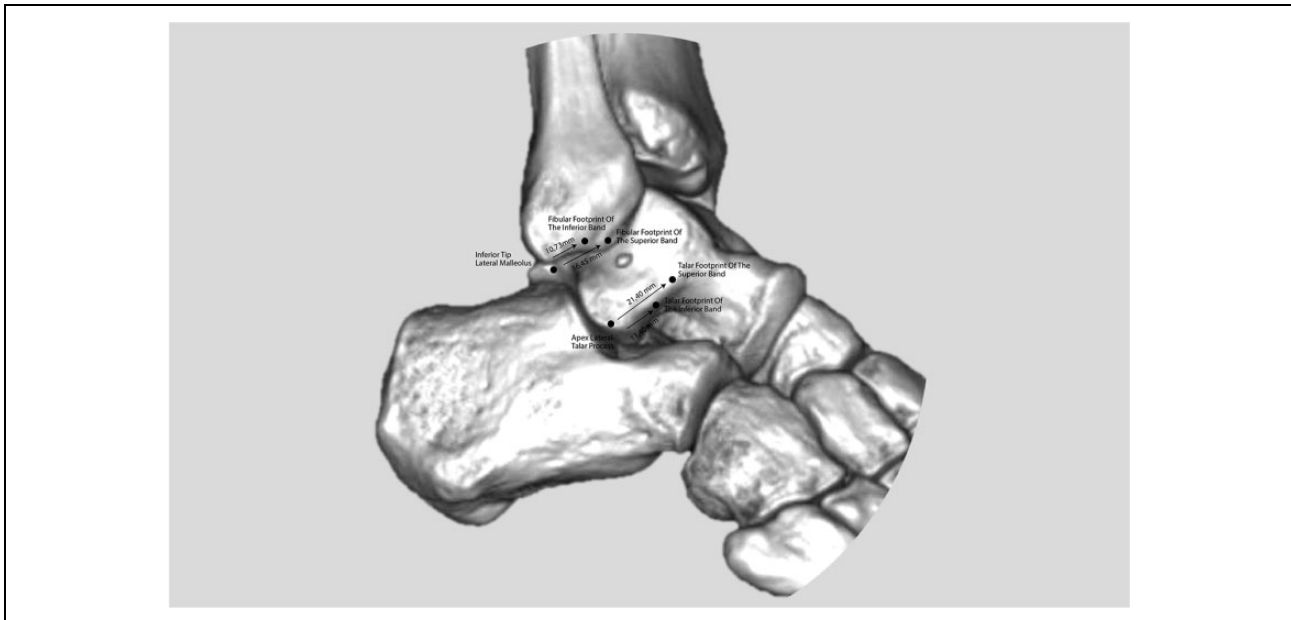


Figure 2. Lateral view of a right ankle in neutral position, fibular and talar foot prints of the superior and inferior bands of ATFL.

Table 2. The diameter of tendons and ligaments according to side and gender.^a

Measurement (mm)	Mean	Left knee	Right knee	Male	Female
ATFL diameter	7.77 ± 0.58	7.73 ± 0.57	7.79 ± 0.62	7.88 ± 0.64	7.52 ± 0.34
Gracilis tendon	4.22 ± 0.37	4.10 ± 0.34	4.29 ± 0.38	4.29 ± 0.39	4.06 ± 0.29
Semitendinosus	5.65 ± 0.66	5.58 ± 0.72	5.70 ± 0.66	5.74 ± 0.71	5.45 ± 0.56
Gracilis + Semitendinosus	9.88 ± 0.99	9.71 ± 1.07	10.0 ± 0.99	10.04 ± 1.05	9.54 ± 0.86

^aValues are mean ± SD.

Table 3. Correlations of the hamstring tendons diameter with the ATFL diameter.

ATFL with Gracilis	R	p
Mean	0.805	0.001 ^a
Left Knee	0.91	0.031 ^b
Right Knee	0.77	0.23
Male	0.79	0.011 ^b
Female	0.82	0.198
ATFL with Semitendinosus		
Mean	0.926	0.001 ^a
Left Knee	0.88	0.044 ^b
Right Knee	0.952	0.001 ^a
Male	0.98	0.001 ^a
Female	0.62	0.378
ATFL with Hamstring		
Mean	0.920	0.001 ^a
Left Knee	0.90	0.34
Right Knee	0.93	0.001 ^a
Male	0.959	0.001 ^a
Female	0.72	0.272

^ap < 0.001: Pearson correlation analysis.

^bp < 0.05: Pearson correlation analysis.

Edama et al. in a cadaver study of 83 legs, the ATFL ligament was closely associated with the ankle capsule and was seen as 33% single band, 57% two band, and 10% three band.²⁰ Milner and Soames cadaver study, 38% single bundle 50% double bundle 12% three bundle was observed.²¹ In our study, we observed a single bundle in 5 patients and a double bundle in 11 patients during ankle dissection. Three bundles were not seen. We used 16 cadavers in this study, and this difference in bundle numbers could be due to the different number of cadavers used in other studies. However, there is no study available evaluating whether anatomical variations have clinical and functional significance in the literature.

It is important to define ligament footprint centers for success in anatomic reconstruction of injured lateral ankle ligaments. Open or arthroscopic techniques for ATFL reconstruction including different tunnel and tendon configurations have been described. For isolated ATFL injury, fixation with single or double tunnel, gracilis and/or semitendinosus graft has been identified, but different tunnel position and tendon configurations are also available due to CFL injury, which is often associated.^{12,22-24} However, there are not enough studies comparing these surgical

techniques. In cadaver studies, there were variations in ATFL fibular and talus adhesion sites and bundle number and the bundle type has been shown to have an impact on fibular and talar adhesion footprint.^{21,25} Similarly, in our study, variations between bundle type and adhesion points were observed. We think that tunnel position and tendon selection may affect clinical outcomes by evaluating these variations. On the other hand, it may not be possible to evaluate the bundle type and footprint of the injured ATFL in chronic cases because of degeneration at ATFL. In our study, similar to the literature, it was observed that the fibular and talar adhesion point has a wide variation. When we evaluate the height and the adhesion points, a moderate correlation was observed in the talar footprint and a weak correlation was observed in the fibular footprint in the single bundle. On the other hand, no correlation was observed in the double bundle. This suggests that it is more difficult to determine the exact footprints in people with multiple bands. In the literature, anatomical variations were observed in the number and thickness of ATFL bundles according to gender. Even differences between the right and left sides of the same cadaver were observed.²⁶ In our study, variations by gender was not observed. According to side, variation was not evaluated because the cadaveric legs were not paired in our study. In the light of these data, we think that anatomical footprints may not be fully evaluated in chronic cases.

It has been shown that the thickness of hamstring grafts varies according to gender and that is correlated with ACL and PCL tendon thickness.^{13,17} In the literature, there is no study showing the relationship between the thickness of ATFL and the thickness of hamstring tendons. In our study, it was found that the thickness of ATFL was correlated with the thickness of hamstring tendons in men. However this correlation was not seen in women. Suitable tendon type and diameter for ATFL surgery have not been defined in the literature. It should be supported by biomechanical and clinical studies whether this incompatibility has a clinical effect or not.

In comparison with other cadaver studies which have defined ATFL, the mean age of the cadavers, the mean BMI measurements have been reported to be similar to our study but this cadaveric specimens mostly embalmed specimens.^{26,27} In our study, we used fresh-frozen, nonpaired specimens that is proper evaluation of tendons and ligament of anthropometry.²⁵ The diameters of the hamstring tendons were measured while applying 89 newtons of force for reduce graft creep in our study that is similar to literature.^{18,28} This force pass from the toe region to the elastic region in the yield curve and provide a more uniform measurement.^{29,30} To reduce the effects of the irregular shapes of the tendons, a double strand was made and measured from the thickest part. Although there are different instruments in the literature as measurement material, digital microcaliper was preferred because it is more sensitive and reliable.¹⁷

In the literature, lots of osseous references point defined for the locations of origins and insertions. Two osseous reference points, anterior tubercle of fibula and tip of the fibula, have been identified for the origins of ATFL.^{31,32} Two osseous reference points, apex of lateral talar process and inferior corner of talar body, have been identified for the insertions of ATFL^{25,31} but there is no reproducible and consistent osseous landmark.^{23,33} In our study, we evaluate the distance from the tip of the fibula and inferior corner of talar body. We believe that these osseous marker is the most reproducible reference landmark because it is easily palpated during lateral ankle surgical exposures. We use small measured parameters, that was reported ± 0.1 mm, so the measured parameters was accurate to that scale.²⁵

There are several limitations in our study. First was the low number of cadavers and second was the average age of cadavers exceeding the average age of patients undergoing ATFL surgery. The absence of any intra-articular pathology, different tendon and ligament pathologies in the evaluated cadavers reduces the possible measurement changes due to degeneration. Third was average results are used in the measurement of irregular shapes of tendons and ligaments. Lastly, the tendons and the ligaments were evaluated only according to their diameters, thus, they should be confirmed by biomechanical and clinical studies.

Conclusion

It was determined that there is not compatibility between the gracilis tendons, the semitendinosus tendon and ATFL in women. It should be supported by biomechanical and clinical studies whether this incompatibility has a clinical effect or not.

Declaration of conflicting interests

The author(s) declared no potential conflicts of interest with respect to the research, authorship, and/or publication of this article.


Ethical approval

This experimental animal study was approved and confirmed that all experiments were performed in accordance with relevant guidelines and regulations by the Acibaden University's Ethics Committee, Decision no: 2020-15/12.

Funding

The author(s) received no financial support for the research, authorship, and/or publication of this article.

ORCID iD

Nazım Karahan  <https://orcid.org/0000-0003-0322-5515>

References

1. Burks RT and Morgan J. Anatomy of the lateral ankle ligaments. *Am J Sports Med* 1994; 22: 72–77.
2. Renstrom FH and Lynch SA. Acute injuries of the ankle. *Foot Ankle Clin* 1999; 4: 697–711.

3. Balduini FC and Tetzlaff J. Historical perspectives on injuries of the ligaments of the ankle. *Clin Sports Med* 1982; 1: 3–12.
4. Fong DT, Hong Y, Chan LK, et al. A systematic review on ankle injury and ankle sprain in sports. *Sports Med* 2007; 37: 73–94.
5. Woods C, Hawkins R, Hulse M, et al. The Football Association Medical Research Programme: an audit of injuries in professional football: an analysis of ankle sprains. *Br J Sports Med* 2003; 37: 233–238.
6. Ferran NA and Maffulli N. Epidemiology of sprains of the lateral ankle ligament complex. *Foot Ankle Clin* 2006; 11(3): 659–662.
7. Waterman BR, Belmont PJ Jr, Cameron KL, et al. Epidemiology of ankle sprain at the United States Military Academy. *Am J Sports Med* 2010; 38(4): 797–803.
8. O’Loughlin PF, Murawski CD, Egan C, et al. Ankle instability in sports. *Phys Sportsmed* 2009; 37(2): 93–103.
9. Gerber JP, Williams GN, Scoville CR, et al. Persistent disability associated with ankle sprains: a prospective examination of an athletic population. *Foot Ankle Int* 1998; 19(10): 653–660.
10. Chen C, Lu H, Hu J, et al. Anatomic reconstruction of anterior talofibular ligament with tibial tuberosity-patellar tendon autograft for chronic lateral ankle instability. *J Orthop Surg (Hong Kong)* 2018; 26(2): 2309499018780874.
11. Golano P, Vega J, de Leeuw PA, et al. Anatomy of the ankle ligaments: a pictorial essay. *Knee Surg Sports Traumatol Arthrosc* 2010; 18(5): 557–569.
12. Song B, Li C, Chen N, et al. All-arthroscopic anatomical reconstruction of anterior talofibular ligament using semitendinosus autografts. *Int Orthop* 2017; 41(5): 975–982.
13. Pujol N, Queinnee S, Boisrenoult P, et al. Anatomy of the anterior cruciate ligament related to hamstring tendon grafts. A cadaveric study. *Knee* 2013; 20(6): 511–514.
14. Giron F, Losco M, Giannini L, et al. Femoral tunnel in revision anterior cruciate ligament reconstruction. *Joints* 2013; 1(3): 126–129.
15. Hosseini A, Lodhia P, Van de Velde SK, et al. Tunnel position and graft orientation in failed anterior cruciate ligament reconstruction: a clinical and imaging analysis. *Int Orthop* 2012; 36(4): 845–852.
16. Taser F, Shafiq Q, and Ebraheim NA. Anatomy of lateral ankle ligaments and their relationship to bony landmarks. *Surg Radiol Anat* 2006; 28(4): 391–397.
17. Yılmaz B, Özdemir G, Keskinöz EN, et al. Comparing dimensions of four-strand hamstring tendon grafts with native anterior and posterior cruciate ligaments. *Biomed Res Int* 2016; 2016: 3795367.
18. Clanton TO, Viens NA, Campbell KJ, et al. Anterior talofibular ligament ruptures, part 2: biomechanical comparison of anterior talofibular ligament reconstruction using semitendinosus allografts with the intact ligament. *Am J Sports Med* 2014; 42(2): 412–416.
19. Strauss EJ, Campbell K, and Bosco JA. Analysis of the cross-sectional area of the adductor longus tendon: a descriptive anatomic study. *Am J Sports Med* 2007; 35(6): 996–999.
20. Edama M, Kageyama I, Kikumoto T, et al. Morphological features of the anterior talofibular ligament by the number of fiber bundles. *Ann Anat* 2018; 216: 69–74.
21. Milner CE and Soames RW. Anatomical variations of the anterior talofibular ligament of the human ankle joint. *J Anat* 1997; 191: 457–458.
22. Guillo S, Cordier G, Sonnery-Cottet B, et al. Anatomical reconstruction of the anterior talofibular and calcaneofibular ligaments with an all-arthroscopic surgical technique. *Orthop Traumatol Surg Res* 2014; 100(8): S413–S417.
23. Takao M, Oae K, Uchio Y, et al. Anatomical reconstruction of the lateral ligaments of the ankle with a gracilis autograft: a new technique using an interference fit anchoring system. *Am J Sports Med* 2005; 33(6): 814–823.
24. Jung HG, Kim TH, Park JY, et al. Anatomic reconstruction of the anterior talofibular and calcaneofibular ligaments using a semitendinosus tendon allograft and interference screws. *Knee Surg Sports Traumatol Arthrosc* 2012; 20(8): 1432–1437.
25. Clanton TO, Campbell KJ, Wilson KJ, et al. Qualitative and quantitative anatomic investigation of the lateral ankle ligaments for surgical reconstruction procedures. *J Bone Joint Surg Am* 2014; 96(12): e98.
26. Raheem OA and O’Brien M. Anatomical review of the lateral collateral ligaments. *Anat Sci Int* 2011; 86: 189–193.
27. Kakegawa A, Mori Y, Tsuchiya A, et al. Independent attachment of lateral ankle ligaments: anterior talofibular and calcaneofibular ligaments—a cadaveric study. *J Foot Ankle Surg* 2019; 58(4): 717–722.
28. Howard ME, Cawley PW, Losse GM, et al. Bone-patellar tendon-bone grafts for anterior cruciate ligament reconstruction: the effects of graft pretensioning. *Arthroscopy* 1996; 12: 287–292.
29. Huijbregts PA and Smith SE. Tendon injury: a review. *J Man Manip Ther* 1999; 7(2): 71–80.
30. Sandrey MA. Effects of acute and chronic pathomechanics on the normal histology and biomechanics of tendons: a review. *Sport Rehabil* 2000; 9: 339–352.
31. Taser F, Shafiq Q, and Ebraheim NA. Anatomy of lateral ankle ligaments and their relationship to bony landmarks. *Surg Radiol Anat* 2006; 28: 391–397.
32. Sindel M. Anatomy of the lateral ankle ligaments. *Turk J Med Sci* 1998; 28: 53–56.
33. Neuschwander TB, Indresano AA, Hughes TH, et al. Footprint of the lateral ligament complex of the ankle. *Foot Ankle Int* 2013; 34(4): 582–586.