



Case report

EML4-ALK-positive lung adenocarcinoma presenting an unusual metastatic pattern in a 29-year-old woman who is alive and well in her third year follow up: A case report



Fatma Tokat ^{a,*}, Handan Zeren ^b, Pinar Barut ^a, Sualp Tansan ^c, Umit Ince ^b

^a Pathology Department, Acibadem Maslak Hospital, Istanbul, Turkey

^b Pathology Department, Acibadem University, Medical Faculty, Istanbul, Turkey

^c Tansan Oncology, Istanbul, Turkey

ARTICLE INFO

Article history:

Received 5 June 2017

Received in revised form

16 July 2017

Accepted 18 July 2017

Keywords:

EML4-ALK translocation

Adenocarcinoma

Subcutaneous metastasis

ABSTRACT

Non-small cell lung cancer (NSCLC) is a frequent tumor entity with high mortality. Although several newly discovered chromosomal translocations and mutations opened new horizons for targeted therapy, literature still lacks large series of NSCLC with chromosomal aberrations and their correlations with histological and clinical features. We present a case of echinoderm microtubule-associated protein-like 4-anaplastic lymphoma kinase (EML4-ALK) translocation positive adenocarcinoma of the lung with an unusual metastatic pattern in a 29-year-old young woman.

Conclusion: Young adult non-smoker female patients with an unexplained pleural effusion and signs of metastatic disease should alert the physicians straight away for all types of malignancies including lung cancer. Any skin lesions should be evaluated carefully, biopsies should be done to exclude metastasis in urgency. On the other hand, an uncommon clinical presentation of a lung cancer requires corresponding molecular testing rapidly in order to offer the best treatment option.

© 2017 The Authors. Published by Elsevier Ltd. This is an open access article under the CC BY-NC-ND license (<http://creativecommons.org/licenses/by-nc-nd/4.0/>).

1. Introduction

Subcutaneous tissue, skeletal muscle and skin metastasis that presents as soft tissue metastasis are rarely reported in the literature [1]. Prevalence of skin metastasis of any cancer type was between 0.75% and 9%. Soft tissue metastasis have appeared usually in the back, chest wall and abdomen [2]. In most cases cutaneous metastasis occur after initial diagnosis of primary cancer. Skin metastasis may appear at the same time or before primary cancer has been diagnosed [3]. Soft tissue metastasis from lung cancer are rarely reported and are a sign of advanced disease and poor prognosis [4]. The discovery of several genetic alterations in NSCLC, has provided best treatment of tumor with oncogene aberrations using molecular targeted drugs [5]. Subcutaneous nodules should alert physicians to take a biopsy. Histopathological, immunohistochemical and molecular studies should be done immediately. We

reported a young woman with ALK positive lung adenocarcinoma that presented itself initially as a single subcutaneous nodule. The patient was treated with tyrosine kinase inhibitors crizotinib and ceritinib. She is in her third year and well.

The 29-year-old female presented a two-month history of an enlarging, slightly painful back nodule near the scapula without any history of trauma or insect bite. She had a history of cytologically benign parapneumonic pleural effusion a year before which was resolved after the treatment. She had no complaints of fever, chills, rash, cough, shortness of breath, hemoptysis, mouth ulcers, arthralgias, dysuria, or loss of weight. She denied tobacco use, second hand smoking, or occupational exposure. Her family history was negative for malignancies. The physical examination revealed a single 2 × 2 cm firm, slightly tender, freely mobile back mass without induration, erythema, or involvement of the skin. She had a normal blood count, basic metabolic panel, liver function tests, and coagulation profile. Superficial soft tissue ultrasonography (USG) showed a 8.8 × 8.6 × 11 mm subcutaneous hypoechoic nodular lesion neighboring the fascia.

With a presumptive diagnosis of folliculitis or soft tissue lesion, the patient underwent excision with wide margins. Operative

* Corresponding author. Acibadem Maslak Hospital, Büyükdere Street, No: 40, Maslak, 34457, Sariyer, Istanbul, Turkey.

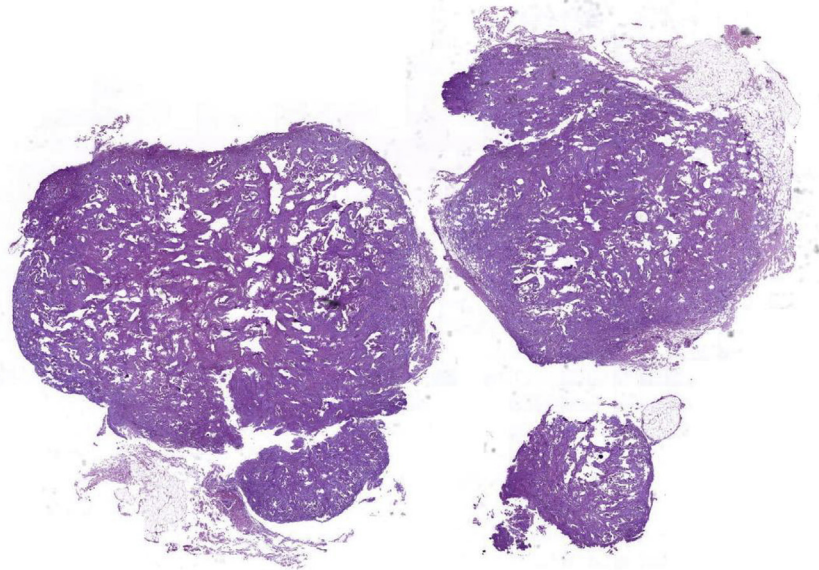
E-mail address: drftokat@hotmail.com (F. Tokat).

findings revealed 11 mm firm, subcutaneous mass superficial to the fascia, surrounded by fat tissue. Histopathology revealed adenocarcinoma with acinar and cribriform pattern (Fig. 1). Immunohistochemical analysis showed strong expression of TTF-1, Napsin A, and cytokeratin 7 in the tumor cells (Fig. 2). These findings were

consistent with lung cancer subcutaneous metastasis. After this diagnosis was made, a positron emission tomography (PET) scan was made which confirmed a hypermetabolic (SUV max: 4.73) mass in the left lower lung lobe, infrahilar, mediastinal and supraclavicular lymph nodes as well as bone involvement (Fig. 3).

(a)

2000 μ m



(b)

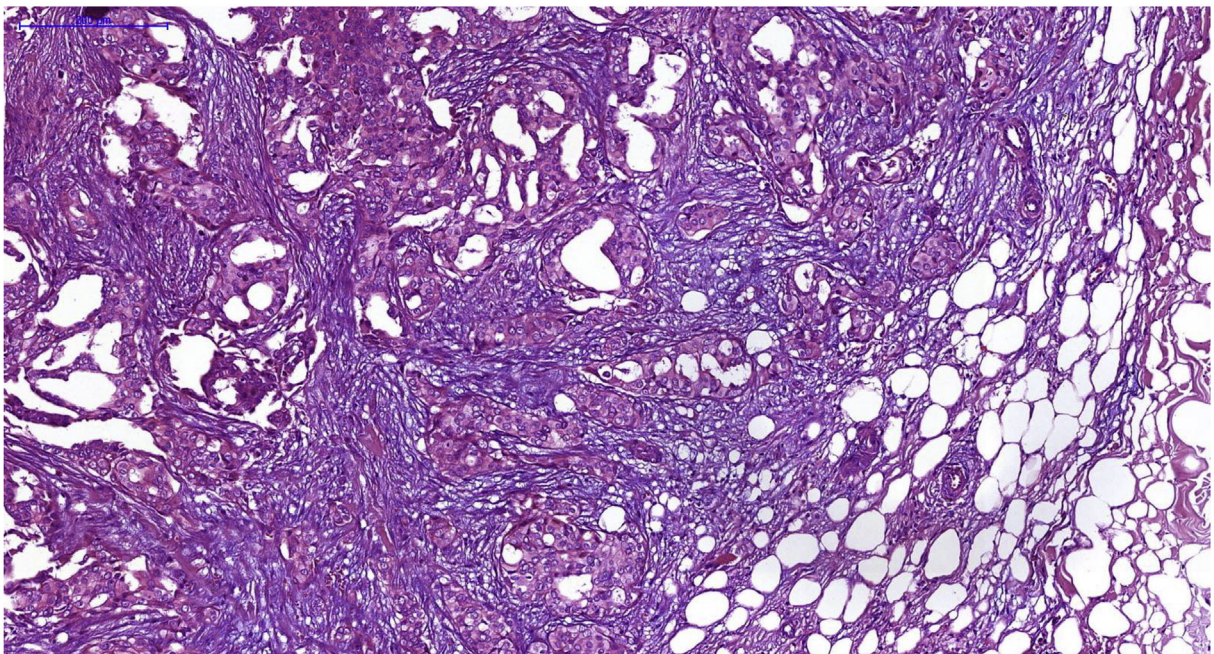
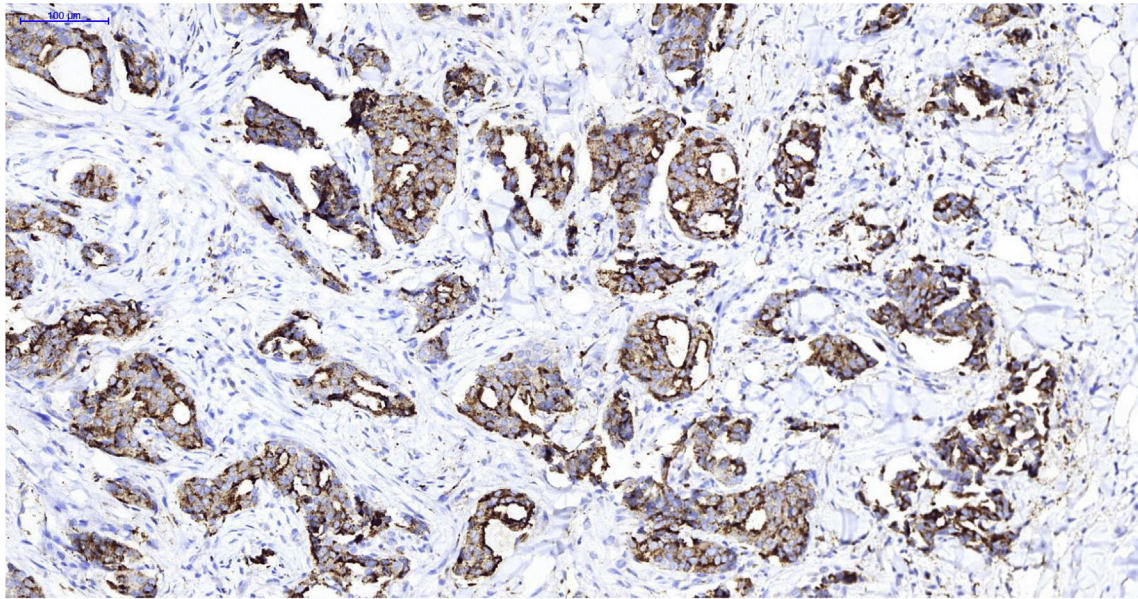


Fig. 1. (a): Subcutaneous tissue with adenocarcinoma. Fig. 1: (b): Acinar and cribriform pattern.

(a)



(b)

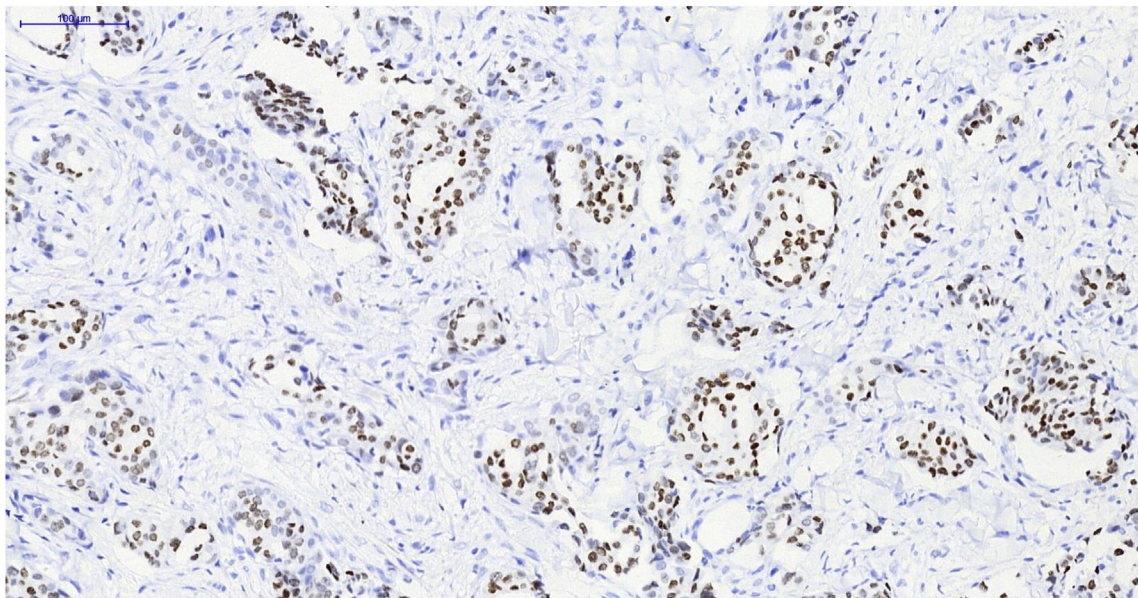


Fig. 2. (a): Tumor cells immunoreactive to Napsin A. Fig. 2: (b): Tumor cells immunoreactive to TTF-1.

At the same time we immediately did a real time PCR for detection Epidermal growth factor (EGFR) mutation and immunohistochemical study for detecting ALK translocation. EGFR gene was analysed using real time PCR test. For the qualitative detection of the gene, DNA was derived from formalin-fixed paraffin-embedded subcutaneous tumor tissue using standard protocol (cobas EGFR Mutation Test, Roche). The EGFR mutation tested negative for mutations in exons 18, 19, 20 and 21 of gene. There was strong diffuse cytoplasmic expression of the ALK protein using a rabbit

monoclonal primary anti-ALK antibody (clone D5F3; Ventana Medical Systems) (Fig. 4), an OptiView 3,3'-diaminobenzidine Immunohistochemistry Detection kit and OptiView amplification kit (Ventana) and we used a fully automated assay using a BenchMark XT automated slide stainer (Ventana Medical Systems). The presence of the EML4-ALK rearrangement was verified by Fluorescence in situ hybridization (FISH), using Zytolight TriCkeck probe for ALK/EML4 (Zytovision molecular diagnostic simplified). 70% of the neoplastic cells were positive for rearrangement (Fig. 5).

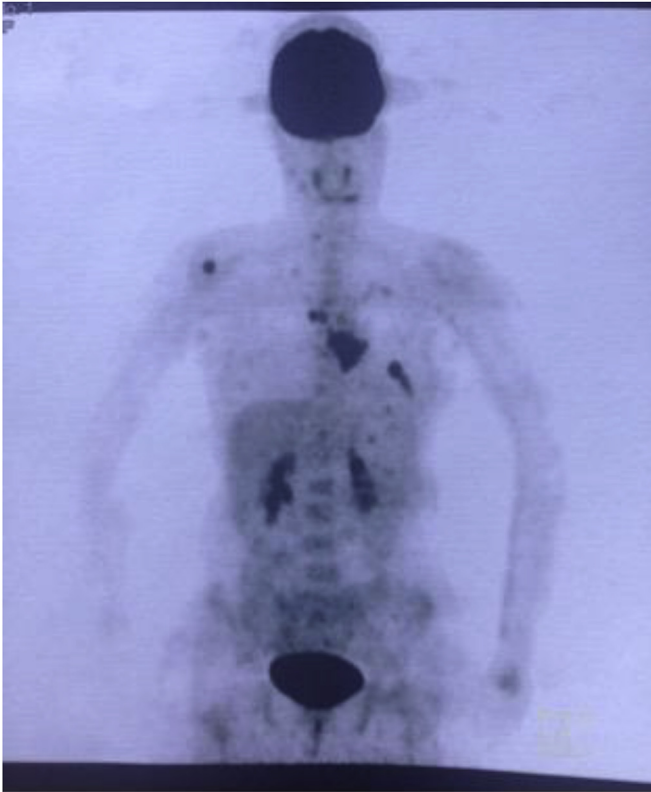

Fig. 3. PET scan.

The patient was treated with an ALK inhibitor, Crizotinib. The tumor response was seen on a CT scan after 4 weeks of treatment (Fig. 6). The patient was well with no evidence of progression for a year. A slight progression was observed in the lung and a suspicious submillimetric lesion in brain after a year. She was treated with Ceritinib which helped her go into remission. Currently it has been three years since the diagnosis and she is doing well once again, on the basis of regularly taking Ceritinib.

2. Discussion

Lung cancer is a well-known cause for cancer related deaths [1]. The majority of patients with advanced NSCLC maintains to be treated with cytotoxic chemotherapy. Novel targeted therapies in NSCLC patients have been developed [6]. Known genetic translocations in lung NSCLC includes EGFR, ALK, KRAS, ROS1, BRAF, RET1, HER2 and recently described neurotrophic tyrosine kinase NTRK1 and Neurogenin 1 (NRG1) [7]. EML4-ALK gene translocation is the most common in lung adenocarcinoma and in ALK rearrangements. In a small subset of NSCLC tumors, a chromosomal inversion event leads to the fusion of a portion of the ALK gene with the EML4 gene. The resulting EML4-ALK fusion protein is constitutively activated and transformed, leading to a state of oncogene addiction [8]. EML4-ALK fusion and other ALK rearrangements are present in a range of 0,1–7,9% of patients with NSCLC. Clinical characteristics associated with the EML4-ALK gene fusion are adenocarcinomas, never or light smoking history and young adults [8–11]. The literature still needs larger series to compare the significance of the young adults of EML4-ALK positive cancers.

The most common localizations of extrapulmonary metastasis in lung cancer are liver, bones, adrenal glands and brain [1,11]. Metastases to the soft tissues, including skeletal muscle, subcutaneous tissue and skin, are rarely reported [1]. The mostly reported primary cancers associated with cutaneous metastasis are lung and colon in males, breast in females mostly in the chest, abdomen, head, and neck [12]. The rate of soft tissue metastasis changes according to the histological types [13]. Adenocarcinoma has been shown to be the most common histological variant associated with soft tissue metastases [12,13]. The correlation between molecular oncogene status and biological behavior may result in a distinct metastatic pattern. At initial diagnosis, ALK gene rearranged adenocarcinomas were found to be underlying in the metastatic sites [14].

ALK rearrangement in lung cancer has been mostly associated with acinar, cribriform pattern, solid growth pattern, and with signet ring cell features [15].

In our case, histopathology revealed adenocarcinoma with an acinar and a cribriform pattern. It was consistent with the literature.

The first treatment of choice for EML4-ALK positive lung cancer

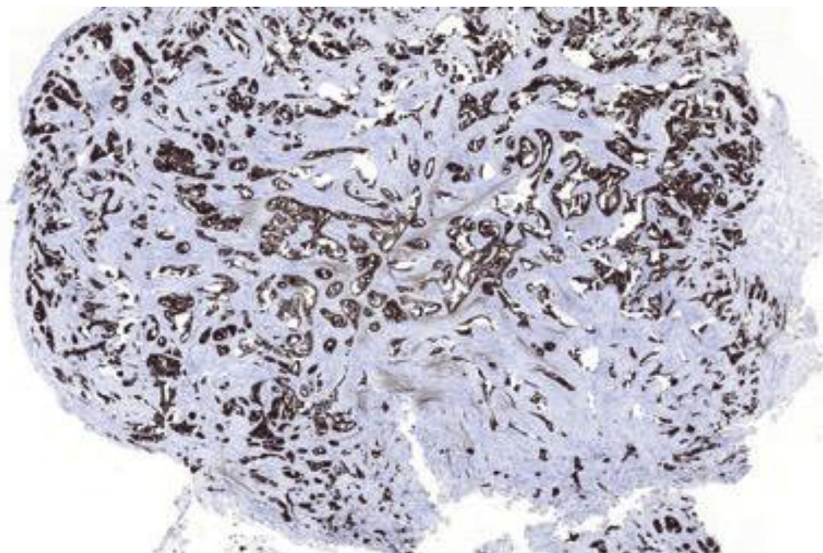


Fig. 4. Tumor cells are diffuse and strongly immunoreactive to anti ALK (D5F3) Ventana.

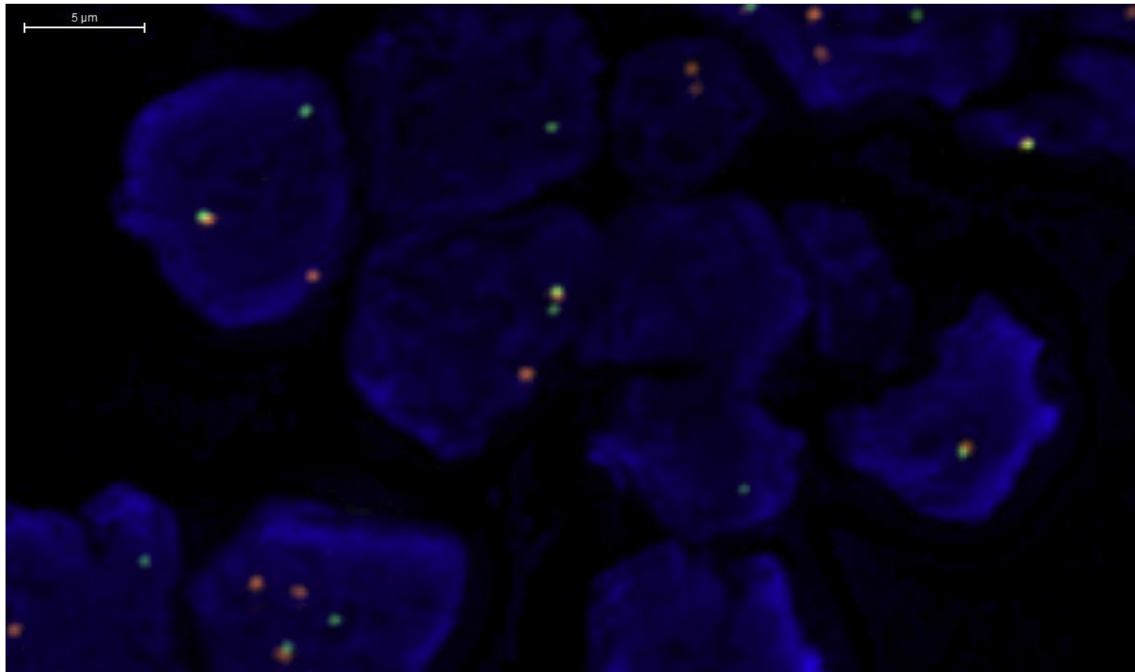


Fig. 5. EML4-ALK gene-positive translocation: split gene signal seen 70% of the nuclei, with separate red and green signals (red signal: telomer side of the ALK gene, green signal: centromere side of the ALK). (For interpretation of the references to colour in this figure legend, the reader is referred to the web version of this article.)

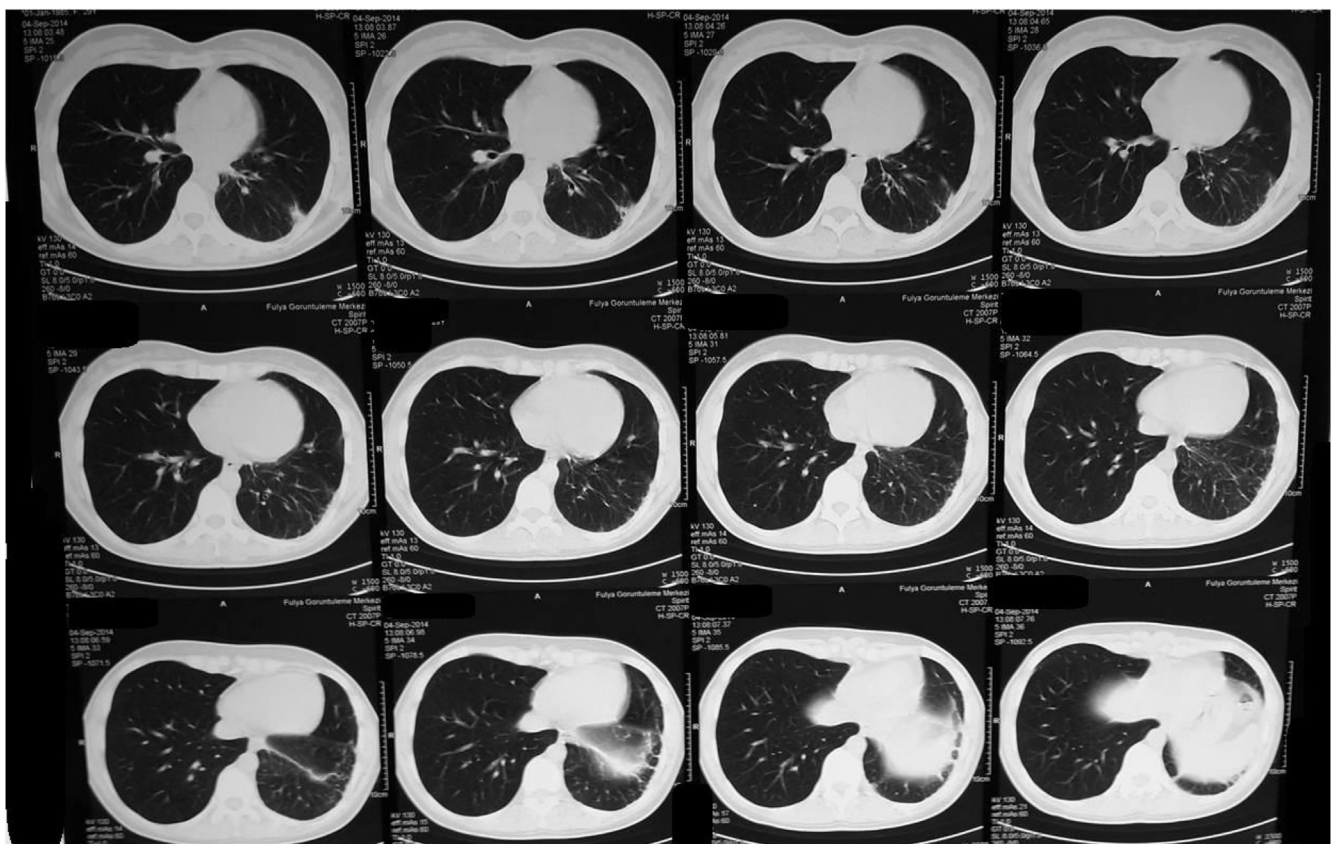


Fig. 6. CT: Tumor response to Crizotinib after treatment.

is TKI (Tyrosine kinase inhibitor) Crizotinib. Crizotinib is a small molecule that suppresses the activity of ALK fusion proteins. It was the first ALK inhibitor to be approved by the FDA for the treatment

of ALK-positive NSCLC [16]. The National Comprehensive Cancer Network advises that patients with advanced ALK-positive NSCLC are treated with crizotinib as a first line treatment. Ceritinib that is

a second-generation ALK inhibitor is recommended for patients who develop crizotinib resistance or who are incapable of tolerating crizotinib [17,18]. Ceritinib is a highly potent and selective ATP-competitive ALK tyrosine kinase inhibitor. Our patient was observed for nearly 3 years with regular CT examinations. In the first year, she was treated with Crizotinib 250 mg taken orally twice daily and progression was detected at the end of the year. The treatment was changed to Ceritinib 750 mg oral once daily and to date, she is doing well, using Ceritinib regularly.

3. Conclusion

We believe ours is the first reported case of EML4-ALK positive adenocarcinoma presenting as subcutaneous nodule, in a non-smoker, otherwise asymptomatic young female, diagnosed incidentally by excision biopsy of the presenting nodule. The metastatic pattern of this NSCLC subtype is different from other lung cancers. Any skin lesions should be evaluated carefully, biopsies should be done to exclude metastasis. This case report highlights the importance of a united multidisciplinary reaction from medical doctors (physician, pathologist, and oncologist) to a tumor genotyping in lung cancer due to their unique tumor biology and rapid effectiveness of the next generation tyrosine kinase inhibitors. Uncommon clinical presentation and presence of metastases in pulmonary adenocarcinoma in younger patients should be presented to physicians in urgency to perform the corresponding molecular tests in order to offer the best treatment options as fast as possible.

Declaration of conflicting interests

The authors declare no potential conflicts of interest with respect to the research, authorship, and/or publication of this article.

Funding

The authors received no financial support for the research, authorship, and/or publication of this article.

References

- [1] C. Perisano, M.S. Spinelli, Graci, et al., Soft tissue metastases in lung cancer: a review of literature, *Eur. Rev. Med. Pharmacol. Sci.* 16 (2012) 1908–1914.
- [2] N.C. Nguyen, B.T. Chaar, M.M. Osman, Prevalence and patterns of soft tissue metastasis: detection with true whole body F-18-FDG PET/CT, *BMC Med. Imaging* 7 (2007) 8.
- [3] S. Pathak, S.R. Joshi, J. Jaison, D. Kendre, Cutaneous metastasis from carcinoma of lung, *Indian Dermatol. Online J.* 4 (3) (2013 Jul-Sep) 185–187.
- [4] C. Baldeo, R. Ali, V. Seeram, J. House, Lung cancer presenting as a soft-tissue metastasis, *Case Rep. Oncol.* 8 (1) (2015 Jan-Apr) 185–188.
- [5] M. Saito, K. Shiraishi, et al., Gene aberrations for precision medicine against lung adenocarcinoma, *Cancer Sci.* 107 (2016) 713–720.
- [6] G. Ali, A. Chella, et al., Response to erlotinib in patient with lung adenocarcinoma harbouring the EML4-ALK translocation: a case report, *Oncol. Lett.* 9 (2015) 1537–1540.
- [7] T. Kohno, T. Nakaoku, K. Tsuta, K. Tsuchihara, S. Matsumoto, K. Yoh, K. Goto, A.L.K.-R.E.T. Beyond, ROS1 and other oncogene fusions in lung cancer, *Transl. Lung Cancer Res.* 4 (2) (2015 Apr), 156–6.
- [8] M.M. Awad, A.T. Shaw, ALK inhibitors in non-small cell lung cancer: crizotinib and beyond, *Clin. Adv. Hematol. Oncol.* 12 (2014) 429–439.
- [9] E. Thunnissen, L. Bubendorf, M. Dietel, G. Elmberger, K. Kerr, F. Lopez- Rios, H. Moch, W. Olszewski, P. Pauwels, F. Penault-Llorca, G. Rossi, EML4-ALK testing in non-small cell carcinomas of the lung: a review with recommendations, *Virchows Arch.* 461 (2012) 245–257.
- [10] R.H. Palmer, E. Vernersson, C. Grabbe, B. Hallberg, Anaplastic lymphoma kinase: signalling in development and disease, *Biochem. J.* 420 (2009) 345–361.
- [11] S. Diem, M. Früh, R. Rodriguez, P. Liechti, C. Rothermundt, EML4-ALK- positive pulmonary adenocarcinoma with unusual metastatic pattern: a case Report, *Case Rep. Oncol.* 6 (2013) 316–319.
- [12] E. Sinha, M. Niazi, G. Diaz-Fuentes, R. Duncalf, An innocent appearing subcutaneous nodule diagnoses a small cell lung cancer in never-smoker female, *Hindawi Publ. Corp. Case Rep. Oncol. Med.* (2014), 268404, 4 pages.
- [13] S. Kumar, A. Gupta, S.K. Diwan, A. Bhake, Subcutaneous swelling as the first clinical manifestation of small cell carcinoma of lung, *Clin. Pract.* 2 (2012) e62.
- [14] R.C. Doebele, X. Lu, C. Sumey, D.A. Maxson, A.J. Weickhardt, A.B. Oton, P.A. Bunn Jr., A.E. Baron, W.A. Franklin, D.L. Aisner, M. Varella-Garcia, D.R. Camidge, Oncogene status predicts patterns of metastatic spread in treatment-naive nonsmall cell lung cancer, *Cancer* 118 (2012) 4502–4511.
- [15] W.D. Travis, E. Brambilla, P.B. Allen, A. Marx, G.N. Andrew, WHO Classification of Tumors of the Lung, Pleura, Thymus and Heart, fourth ed., 2015, pp. 22–37. Lyon.
- [16] D. Kazandjian, G.M. Blumenthal, et al., FDA approval summary: crizotinib for the treatment of metastatic non-small cell lung cancer with anaplastic lymphoma kinase rearrangements, *Oncologist* 19 (2014) e5–e11.
- [17] H. El-Osta, R. Shackelford, Personalized treatment options for ALK-positive metastatic non-small-cell lung cancer: potential role for Ceritinib, *Pharmacogenomics Personal. Med.* 8 (2015) 145–154.
- [18] National Comprehensive Cancer Network (NCCN), Clinical Practice Guidelines in Oncology, NCCN, Fort Washington, PA, 2015, Version 5. .