




Perpendicular drill bit alignment provides a practical guidance to determine the appropriate suture anchor insertion angle during acetabular labral repair

Abdul Veli Ismailoglu ^{1*}, Omer Ozdogmus², Muhammed Ilkay Karaman³, Asim Kayaalp⁴ and Baris Kocaoglu³

¹Department of Anatomy, Faculty of Medicine, Acibadem Mehmet Ali Aydinlar University, Kayisdagi Cad. No: 32, Atasehir, Istanbul 34752, Turkey,

²Department of Anatomy, Faculty of Medicine, Marmara University, Maltepe Basibuyuk Yolu, No: 9, Maltepe, Istanbul 34854, Turkey, ³Department of Orthopedic Surgery, Faculty of Medicine, Acibadem Mehmet Ali Aydinlar University, Kayisdagi Cad. No: 32, Atasehir, Istanbul 34752, Turkey and and

⁴Department of Orthopedic Surgery, Ankara Cankaya Hospital, Barbaros Sk. No: 44, Cankaya, Ankara 06700, Turkey.

*Correspondence to: A. V. Ismailoglu. E-mail: abdulveli.ismailoglu@acibadem.edu.tr

ABSTRACT

The safe acetabular rim angle is an anatomical measurement used to determine the safety margin when inserting suture anchors. The purpose of the present study was to find out whether aligning the drill bit perpendicularly during arthroscopic surgery can provide a reference point for determining an appropriate angle to facilitate the suture anchor insertion and to prevent extra- and intra-articular perforations. One hundred computed tomographic hips were used to reconstruct three-dimensional acetabular hip models. Each model was radially sectioned at the 4 o'clock, 3 o'clock and anterior inferior iliac spine (AIIS) positions (that corresponded mainly to the 2:20 clock position). A perpendicular reference line, representing a perpendicular drill bit alignment, was drawn for each position within the acetabular model, and its relation to the safe acetabular rim angle was measured. The length of the perpendicular reference line and the effect of gender on measurements were also evaluated. The mean safe acetabular rim angle at the 3 o'clock position was significantly smaller compared to other clock positions ($P < 0.001$). The perpendicular reference line was located out of the safe acetabular rim angle in 28 cases (%28), mostly in female acetabula at the 3 o'clock position, and relative to the perpendicular reference line the required minimal angle was $4^\circ \pm 2.3^\circ$ to place the anchor in the safe acetabular rim angle to avoid extra-articular perforation. The perpendicular reference line was shortest at the 3 o'clock position, and its mean length was shorter in female acetabula at all clock positions ($P < 0.001$). Aligning the drill bit perpendicular to the acetabular opening plane during an arthroscopic anchor placement is a practical way to estimate and target the position of the safe acetabular rim angle to avoid anchor perforations. Based on measurements from a perpendicularly aligned drill bit, the drill bit should be directed towards the joint minimally by 4° to avoid extra-articular perforations and maximally by 30° to avoid intra-articular perforations.

INTRODUCTION

Acetabular labrum is a fibrocartilage tissue creating a vacuum seal between the acetabulum and the femoral head that helps maintain hip joint stability through the reduction of excessive movements [1, 2]. Functional impairment of the labrum has been shown to lead to joint instability with cartilage degeneration, eventually resulting in osteoarthritis [3–5]. The acetabular labrum decreases the cartilage stress, strain and consolidation through labral sealing, which provides a pressurized intra-articular fluid layer to further support the load and to protect the articular surface [6, 7]. One other critical role of the labrum is to expand the contact area, which is essential to reduce the cartilage contact pressure [8, 9].

As previously shown by Greaves *et al.*, labral resection increases the contact pressure relative to an intact labrum,

resulting in early degenerative changes [4]. Therefore, labral repair is considered essential. Over the years, a general consensus has been reached that labrum functions can be maintained substantially when the labrum is properly repaired and should be preferred over labral resection [2, 10].

Suture anchors are commonly used at the anterior acetabulum to refixate the anterior labrum due to its high vulnerability. Furthermore, most anchor perforations occur here due to the shallow bony vault characteristic of the anterior acetabulum, which indicates the importance of the acetabular rim anatomy for the safety of the anchor placement [11–13]. The use of suture anchor represents the most common technique to reattach the torn labrum to the acetabular rim, and it has been suggested that the suture anchor should be placed onto the bony acetabulum vault using an appropriate angle to avoid penetration into the hip

joint or pelvis [11, 14]. Although a safe acetabular rim angle, defined as the angle between the subchondral margin and the outer cortex of the acetabulum, has been utilized to avoid penetration [15–17], how to target the drill bit to reach the safe acetabular angle has not been thoroughly researched.

The safe acetabular rim angle is an anatomical measurement used to determine the safety margin when inserting suture anchors. Inserting the suture anchor within the safe acetabular rim angle will prevent iatrogenic anchor perforations. Therefore, a larger safe acetabular rim angle would provide a higher safe insertion area within the acetabular bony vault. Targeting the safe acetabular rim angle thus is essential for the safety of the arthroscopic suture anchor insertion.

The purpose of the present study was to find out whether aligning the drill bit perpendicularly during arthroscopic surgery can be used as a reference point for measuring the required angle to prevent extra- and intra-articular perforations. In other words, a perpendicularly aligned drill bit can serve as a practical guide to measure the angle for targeting the safe acetabular rim angle and can help to estimate the required minimal and maximal angles to avoid perforations. For this purpose, a perpendicular reference line representing the perpendicularly aligned drill bit was drawn, and its relation to the fixed lines indicating the margins of the safe acetabular rim angle was noted. The effect of gender on the safe acetabular rim angle and the safe drill depth were evaluated at the 2:20 [anterior inferior iliac spine (AIIS)], 3 o'clock and 4 o'clock positions using three-dimensional acetabular hip models.

MATERIALS AND METHODS

In this retrospective study, computed tomographic (CT) abdominal and pelvic scans obtained between June 2017 and January 2020 from 54 randomly selected patients were examined along with their clinical records. Scans also included bilateral hip images. The CT scans were obtained with a Somatom Force device (Siemens Healthineers Global, Germany) using standard techniques at 100 kVp and 256 mAs, with a slice thickness of 0.5–1.0 mm and a resolution of 512×512 pixels (voxels approximately $0.7 \times 0.7 \times 0.5 \text{ mm}^3$).

Four patients were excluded due to the presence of bilateral osteoarthritis and acetabular fractures. Measurements were performed using the remaining bilateral hip images from 50 patients (23 male and 27 female) with a mean age of 43 ± 14 years (range: 22–69 years). All scans were fully anonymized, and the study protocol was approved by University Research Ethics Board (No. 2019-17/27).

DICOM format CT data of each hip were imported to Mimics software (Materialize, Leuven, Belgium) to reconstruct three-dimensional geometric hip models and to perform measurements. The femoral head was removed from the acetabulum to view the acetabular model. A conventional clockface reference was constructed, and the midpoint of the acetabular notch corresponded to the midpoint of the transverse acetabular ligament at the 6 o'clock position [13, 17]. For study purposes, this was represented by an acetabular line extending between the most distinct two points of the width of the acetabular notch (Fig. 1). The other clock positions were then defined relative to the 6 o'clock position.

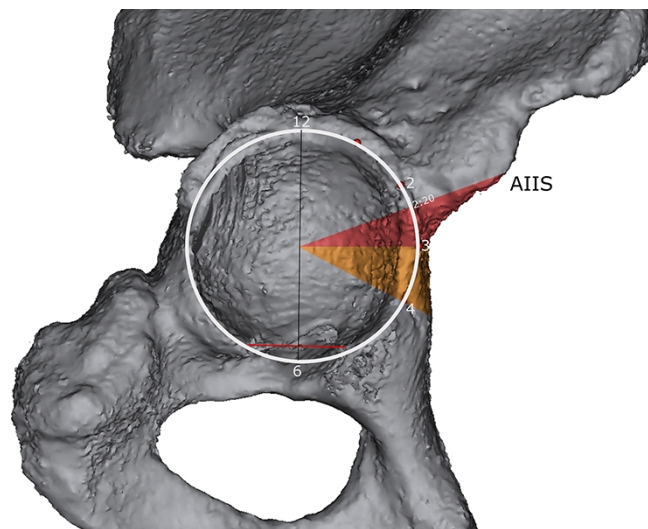


Fig. 1. The three-dimensional geometric model of the hip bone and acetabular slices at the AIIS, 3 o'clock and 4 o'clock positions. The circle represents the acetabular opening plane. The 6 o'clock position was located at the midpoint of the acetabular line corresponding to the transverse acetabular ligament.

The acetabular models were positioned according to the defined acetabular opening plane [17], which is indicated by a circle that passes through the tips of the anterosuperior, the anteroinferior and the posteroinferior rim prominences. The pelvic tilt of the acetabular models was also determined by aligning the acetabular line transversely. After the pelvic tilt was correctly positioned, the right acetabular model was radially sectioned perpendicular to the acetabular opening plane at the right AIIS, 3 o'clock and 4 o'clock positions that correspond to the left acetabular model at the left AIIS, 9 o'clock and 8 o'clock positions, respectively (Fig. 1). The most common location of AIIS was 2:20 clock position, ranging between 2:10 clock to 2:30 clock positions.

The capsular side of the labral insertion was recommended as a suture anchor entry point during acetabular labral repair [18–20]. Since the labrum is located between 2.3 and 2.6 mm from the capsular side of the rim that did not significantly differ at the superior, anterior and anterosuperior acetabular rims [16], a 2.5-mm distance was measured at each clock position from the tip of the bony acetabular rim to the capsular side of the rim to estimate the entry point. Two straight lines representing drill depth, referred to as the subchondral line and outer cortex line, were drawn [16, 17] to define the safe acetabular rim angle. The line was 19.5 mm long, which is the manufacturer's recommended drill depth to secure anchor into the bone for the 2.9-mm Pushlock or Fibertak anchor systems (Arthrex, Naples, USA). These systems are commonly used in acetabular labral repair practice. The subchondral line touched the subchondral bone margin, and the outer cortex line was placed at a position targeted farthest from the articular cartilage, where purchase in bone was possible without penetrating the acetabular wall (Fig. 2). As the entry point and drill depth were standardized, the measured safe acetabular rim angle would only depend on the clock position.

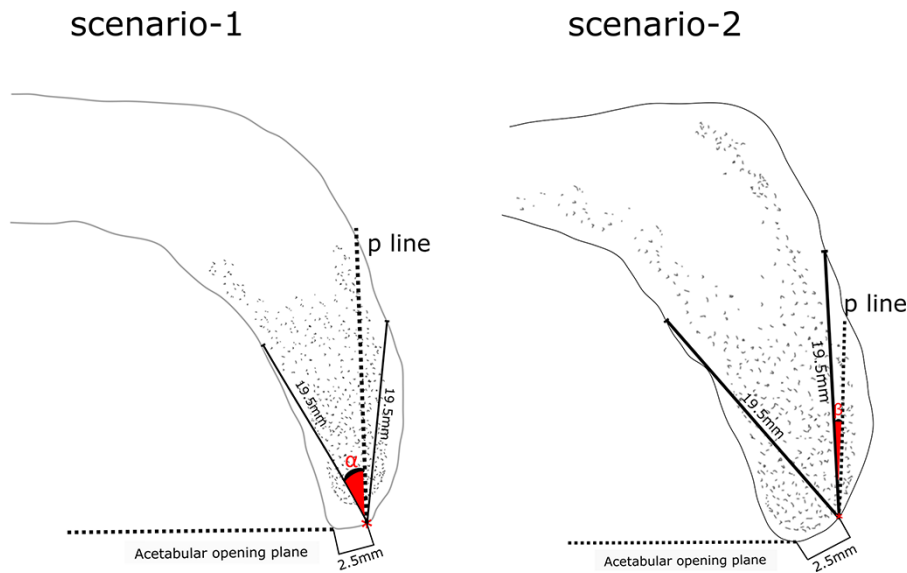


Fig. 2. Superior view of two different sectioned acetabula at the 3 o'clock position. The safe acetabular rim angle was measured by drawing fixed 19.5-mm lengths of the subchondral line and the outer cortex line. The perpendicular reference line (p line) is stretched along with the bony acetabular vault. The p line is located in the safe acetabular rim angle (Scenario 1). α angle formed between the p line and the subchondral line; exceeding α angle will result in intra-articular perforation. The p line is located out of the safe acetabular rim angle (Scenario 2). β angle, formed between the p line and the outer cortex line, indicates the required minimal angle to target the safe acetabular rim angle.

*Refers to the entry point located at 2.5-mm distance from the tip of the acetabular rim to the acetabulum capsular side.

A line, referred to as the 'perpendicular reference line' (the p line) and representing the perpendicularly aligned drill bit, was drawn perpendicular to the acetabular opening plane starting at the entry point and extending along the bony acetabular vault. The length of the perpendicular reference line drawn in the vault was recorded. When the perpendicular reference line remained within the safe acetabular rim angle, this was recorded as Scenario 1. In that case, the angle formed between the perpendicular reference line and the subchondral line (α angle) was also recorded (Fig. 2). The α angle represents the maximal joint targeted drilling angle to purchase the suture anchor in the acetabular vault, avoiding intra-articular perforations.

In cases where the perpendicular reference line was located outside the safe acetabular rim angle, which was referred to as Scenario 2, the angle formed between the outer cortex line and the perpendicular reference line (β angle) was recorded (Fig. 2). The β angle indicates the minimal joint targeted drilling angle required to insert the suture anchor into the safe acetabular rim angle to avoid intra-pelvic perforations.

The acetabulum had a characteristic shallow bony vault only at the AIIS position out of the outer cortex line, which may increase the risk of anchor penetration. Thus, the minimal bone thickness at the AIIS position, the shortest distance, from the entry point to the outer cortex was recorded (Fig. 3).

Statistical analysis

Two independent observers performed all measurements, including the acetabular model positioning and sectioning, and interobserver agreement of the measurements was assessed. The reliability of the measurements was evaluated by interclass correlation coefficients using the mean of two measurements made by each observer.

Student's *t*-test was used to assess differences between right and left hips. Differences between clock position measurements and genders were evaluated with one-way analysis of variance (ANOVA). The Tukey's post hoc analysis was used for all significant ANOVA results. Descriptive statistics were provided as mean \pm standard deviation. Statistical significance was assumed when *P* was <0.05 . SPSS software (SPSS Inc, Chicago, IL) was used for statistical analyses.

RESULTS

As there were no differences between right ($n = 50$) and left ($n = 50$) acetabula ($P > 0.5$), all left clock positions were mirrored and therefore were presented as right clock positions ($n = 100$). The safe acetabular rim angles according to clock positions are shown in Table I. The mean safe acetabular rim angle at the 3 o'clock position was significantly smaller compared to other clock positions ($P < 0.001$).

The location of the perpendicular reference line varied depending on the clock position and anatomy of the anterior acetabulum. The perpendicular reference line remained in the safe acetabular rim angle in all cases at the AIIS position ($n = 100$). However, the perpendicular reference line was located out of the safe acetabular rim angle in 22 cases at the 3 o'clock position and in 6 cases at the 4 o'clock position (Table II). The α and β angles are shown in Table II. The mean α angle between all the clock positions was not significantly different ($P > 0.05$).

The mean length of the perpendicular reference lines in males and females was given with the *P* value indicated in Table III. The perpendicular reference line was shortest at the 3 o'clock position, and its mean length was shorter in female acetabula at all

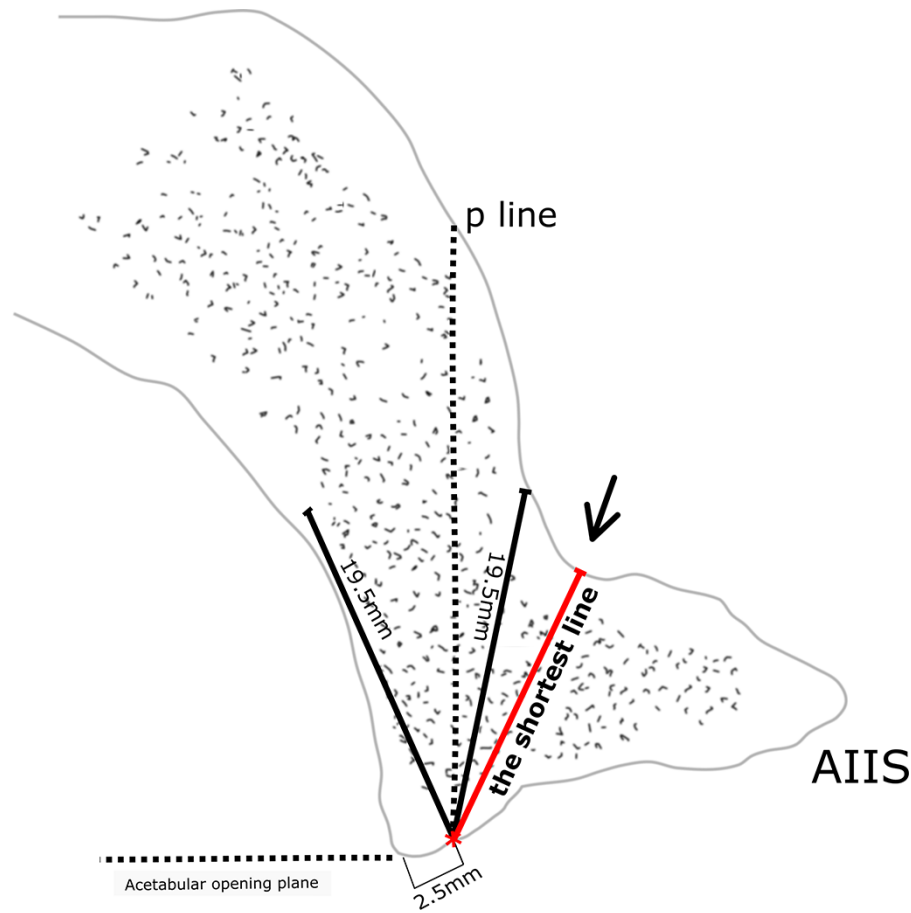


Fig. 3. Superior view of sectioned acetabulum at the AIIS position corresponding to the 2:20 clock position. Arrow indicates the depressed region of the acetabular vault corresponding to the ‘psoas tunnel’ hidden by the AIIS, which is dangerous for the suture anchor’s safety. The p line at the AIIS position is fitted in Scenario 1 in all acetabular models.

Table I. The safe acetabular rim angle (°)

Clock position	Scenario 1			Scenario 2	
	Mean	Gender	P (male versus female)	Mean	Gender
AIIS (2:20)	(n = 100) 45.2 ± 6.4	Male (n = 46) 44.5 ± 5.5 Female (n = 54) 45.8 ± 7.1	>0.05	(n = 0) NA	NA NA
3 o'clock	(n = 78) 38.3 ± 5.7	Male (n = 45) 40.4 ± 5.4 Female (n = 33) 35.4 ± 5.0	<0.001	(n = 22) 31.9 ± 4.0	Male (n = 1) 32.0 ± NA Female (n = 21) 31.9 ± 4.1
4 o'clock	(n = 94) 45.7 ± 8.5	Male (n = 46) 51.5 ± 6.8 Female (n = 48) 40.1 ± 5.9	<0.001	(n = 6) 30.5 ± 5.6	Male (n = 0) NA Female (n = 6) 30.5 ± 5.6

NA, not available.

clock positions ($P < 0.001$). The length of the perpendicular reference line was shorter than 19.5 mm at the 3 o'clock position in 25 cases and at the 4 o'clock position in 6 cases (Table III). The mean shortest distance was 14.2, and it was significantly shorter in females ($P < 0.01$).

DISCUSSION

In this study, assessment of the safe acetabular rim angle and its relationship with a perpendicular reference line provided further insights with the potential to facilitate safe anchor insertion within the safe acetabular rim angle and providing a means to

Table II. Measurements of the α and β angles ($^{\circ}$)

Clock position	Scenario 1 α Angle			Scenario 2 β Angle	
	Mean	Gender	P (male versus female)	Mean	Gender
AHS (2:20)	(n = 100) 31.2 \pm 4.2	Male (n = 46) 29.4 \pm 3.5 Female (n = 54) 32.7 \pm 4.3	>0.05	(n = 0) NA	NA NA
3 o'clock	(n = 78) 31.4 \pm 5.0	Male (n = 45) 31.1 \pm 5.0 Female (n = 33) 32.0 \pm 4.9	>0.05	(n = 22) 3.3 \pm 2.2	Male (n = 1) 1.0 \pm NA Female (n = 21) 3.4 \pm 2.2
4 o'clock	(n = 94) 30.0 \pm 4.5	Male (n = 46) 29.9 \pm 4.4 Female (n = 48) 30.2 \pm 4.7	>0.05	(n = 6) 3.6 \pm 2.3	Male (n = 0) NA Female (n = 6) 3.6 \pm 2.3

NA, not available.

Table III. Length of the perpendicular reference line (mm)

Clock position	Mean (min-max)	Scenario 1			Scenario 2		
		Gender and P value	No. of samples shorter than 19.5 mm	Mean (min-max)	Gender and P value	No. of samples shorter than 19.5 mm	
AHS (2:20)	29.4 (22-40)	Male (n = 46) 30.8 \pm 3.2 Female (n = 54) 28.2 \pm 3.7	<0.001	0/100 (0%)	NA	NA	0/0
3 o'clock	24.5 (15-37)	Male (n = 45) 26.3 \pm 4.0 Female (n = 33) 22.3 \pm 3.6	<0.001	4/78 (5%)	17.4 (13-26)	Male (n = 1) 19 \pm NA Female (n = 21) 17.3 \pm 2.6	21/22 (95%)
4 o'clock	25.9 (20-38)	Male (n = 46) 29.6 \pm 2.9 Female (n = 48) 22.5 \pm 1.8	<0.001	0/94 (0%)	18.1 (17-19)	Male (n = 0) NA Female (n = 6) 18.1 \pm 0.9	6/6 (100%)

avoid extra- and intra-articular penetrations. The perpendicular reference line used herein represents a practical guide that can be readily established during arthroscopic surgery by aligning the drill bit perpendicularly to the acetabular opening plane. After the drill bit is aligned perpendicularly, the safe acetabular rim angle can be easily targeted to place the suture anchor confidently by considering minimal and maximal insertion angles reported in this study. In addition, our study provided further understanding of the maximal available drilling depth of the bony acetabular vault to avoid anchor perforations taking into account the gender differences using three-dimensional acetabular modelling.

The observed magnitude of the safe acetabular rim angle in our study was at odds with previous reports [16, 17], mainly due to the use of the acetabular rim as the entry point in the latter [17], as opposed to the use of the capsular side of the acetabular rim [18-20] (2.5-mm distance away from the tip of the bony acetabular rim [16]) in our study. Also, in Hernandez and McGrath's study, safe acetabular rim angle measured in nine fresh frozen cadaver samples was smaller than ours, presumably because the

drill diameter was taken into consideration by these authors in their measurements [16].

In an effort to minimize the risk of anchor penetration, different portals as well as curved and straight drill guides were compared in terms of safety [13, 21-24]. Studies identified the safe acetabular rim angle and attempted to evaluate the effect of the entry point, the acetabular anatomy and the size and length of the drill bit [21-23]. However, in addition to identifying the determinants of the magnitude of the safe acetabular rim angle, it is also crucial to accurately determine the location of the safe acetabular rim angle during arthroscopic labral repair for safe insertion of suture anchor.

To facilitate this procedure, we consider that aligning the drill bit perpendicular to the acetabular opening plane may serve as a guide during arthroscopic surgery to understand its location relative to the safe acetabular rim angle. For this purpose, a perpendicular reference line was drawn to represent the perpendicular drilling that extended along the bony acetabular vault. According to this scheme, when the perpendicular reference line

was purchased within the safe acetabular rim angle, perpendicular drilling would not cause perforation (Scenario 1). However, when this line was located outside the boundaries of the safe acetabular rim angle, perpendicular drilling would be expected to cause intra-pelvic perforation (Scenario 2). In this latter scenario, the required minimal angle in relation to the perpendicular reference line was measured in order to target the safe acetabular rim angle and to avoid perforation.

In Scenario 1, an α angle was measured to define maximally available bone stock without causing intra-articular perforation. According to our results, starting at the labral insertion, a maximum target angle of $30^\circ \pm 5.0^\circ$ towards the joint at the anterior acetabulum should be adopted, with the perpendicular reference line representing 0° . Targeting the drill bit beyond 30° would cause intra-articular perforation.

In our series, 28 cases fitted in Scenario 2, and to avoid intra-pelvic perforation, the surgeon should target the drill bit towards the joint using a minimum angle of $4^\circ \pm 2.3^\circ$ (the β angle), securing an entry within the safe acetabular rim angle. Among 22 cases, 21 of them were females, and the perpendicular reference line was located out of the safe acetabular rim angle at the 3 o'clock position, mainly due to a narrower safe acetabular rim angle at that position. In support of this, previous studies showed a higher risk for intra-pelvic perforations at the 3 o'clock position, both for mid-anterior and for distal anterolateral (DALA) portals [12, 16].

Our findings showed that starting at the capsular side of the labral insertion, the mean range of the safe drilling arc (maximal angle–minimal angle) of the anterior acetabulum was 30° – 4° . When standard deviations of the maximal angle and the minimal angle are considered (Table II), the safe drilling arc could be as narrow as 25° – 6° in some cases. Hence, anchor placement at the maximal or minimal limit of the safe drilling arc can be dangerous in terms of perforations. Targeting the middle of the safe drilling arc would ensure the safest bony vault for anchor insertion.

In the present study, the length of the perpendicular reference line starting at the labral insertion and representing the maximally available bone depth was also measured to determine whether sufficient bone depth was present to prevent drill perforations. The 3 o'clock position had a higher risk for perforations in terms of not only the safe rim angle but also the bony vault thickness. In 25 cases at the 3 o'clock position and 6 cases at the 4 o'clock position, the available bone thickness was shorter than 19.5 mm, which can be overcome by directing the drill bit towards the joint. As one would expect in Scenario 2, the bone stock was not enough to secure the suture anchor when the perpendicular reference line was located out of the safe acetabular rim angle. However, despite a perpendicular reference line being located in the safe acetabular rim angle, the depth of the bone was shorter than 19.5 mm in four cases at the 3 o'clock position (Table III), suggesting that the drill should be targeted towards the joint at a wider angle to avoid intra-pelvic perforations. Nevertheless, because of the narrow safe acetabular rim angle at the 3 o'clock position, targeting the joint at angles exceeding 30° is likely to result in intra-articular perforation.

The measurement at the AIIS position, corresponding to the AIIS where 'psoas valley' starts [22], showed that AIIS medially houses a major depression in continuity with the so-called 'psoas tunnel' [11] (Fig. 3). The depression in the bone, which

is located beyond the outer cortex line, leads to a decrease in the available bone thickness (the mean thickness was 14.2 mm) that is insufficient for anchor insertion and that will greatly increase the risk of penetration. This requires particular attention by the surgeon, as it may result in a false image of safety for anchor insertion using a wide angle [17], since the depression created by the psoas tunnel is concealed by AIIS. To avoid penetration at AIIS (2:20) position, this bony depression should be taken into consideration, and the drill bit should be targeted towards the joint, not the pelvic region.

Several limitations of our study should be mentioned. Acetabula selected for the study were free of significant pathologies such as osteophytes, dysplastic hips, pincer lesions or other deformities. Therefore, our results may not be applicable to acetabula with significant morphological abnormalities. During labral repair, depending on the preferred arthroscopic portal and the surrounding soft tissue of the hip, positioning the drill angle may be challenging. In addition, the ability to measure these angles intra-operatively is limited. Suggested angles in this study are only applicable for those anchor systems that require 19.5-mm or lower drill depth. Our measurements did not consider the diameter of the drill bit, rather it is represented by a line; therefore, the surgeon should consider the fact that the actual angle may be smaller than reported in this study. However, a perpendicular alignment of the drill irrespective of the patient position seems to reliably ensure the entry within the safe acetabular rim angle and utilization of a safe drilling angle arc. Our study also provides further insights into gender differences regarding the safe acetabular rim angle and regarding the available acetabular bone thickness at certain positions independent of the diameter of the drill bit.

CONCLUSION

Aligning the drill bit perpendicularly to the acetabular opening plane during arthroscopic anchor placement appears to provide a practical estimation and targeting of the safe acetabular rim angle. Using this approach, the anchor can be purchased into the safe acetabular rim angle and anchor perforations can be avoided. Using the measurements with the perpendicularly aligned drill bit, the drill bit should be directed towards the joint at a minimal angle of 4° to avoid extra-articular perforations and at a maximal angle of 30° to avoid intra-articular perforations. Within the boundaries of this angle arc, the suture anchor can be confidently purchased into the safe acetabular rim angle. Although AIIS offers a greater acetabular rim angle, the presence of a significant bony depression poses a risk for drill perforation in the psoas tunnel. Both the length of the perpendicular reference line and safe acetabular rim angle were the smallest at the 3 o'clock position and in the female acetabula.

DATA AVAILABILITY

The data underlying this article will be shared on reasonable request to the corresponding author.

ACKNOWLEDGEMENTS

The content is solely the responsibility of the authors and does not necessarily represent the official views of the Scientific and Technological Research Council of Turkey (TUBITAK).

FUNDING

Scientific and Technological Research Council of Turkey (TUBITAK) (grant no. 2211/A-1649B031603214); internal research funding of Acibadem Mehmet Ali Aydinlar University (ABAPKO: 2020/01/13).

CONFLICT OF INTEREST STATEMENT

None declared.

REFERENCES

- Cashin M, Uhthoff H, O'Neill M *et al*. Embryology of the acetabular labral-chondral complex. *J Bone Joint Surg* 2008; **90**: 1019–24.
- Crawford MJ, Dy CJ, Alexander JW *et al*. The 2007 Frank Stinchfield Award. The biomechanics of the hip labrum and the stability of the hip. *Clin Orthop Relat Res* 2007; **465**: 16–22.
- Ferguson SJ, Bryant JT, Ganz R *et al*. An in vitro investigation of the acetabular labral seal in hip joint mechanics. *J Biomech* 2003; **36**: 171–8.
- Greaves LL, Gilbert MK, Yung AC *et al*. Effect of acetabular labral tears, repair and resection on hip cartilage strain: a 7T MR study. *J Biomech* 2010; **43**: 858–63.
- Philippon MJ, Michalski MP, Campbell KJ *et al*. An anatomical study of the acetabulum with clinical applications to hip arthroscopy. *J Bone Joint Surg* 2014; **96**: 1673–82.
- Nepple JJ, Philippon MJ, Campbell KJ *et al*. The hip fluid seal—Part II: the effect of an acetabular labral tear, repair, resection, and reconstruction on hip stability to distraction. *Knee Surg Sports Traumatol Arthrosc* 2014; **22**: 730–6.
- Philippon MJ, Nepple JJ, Campbell KJ *et al*. The hip fluid seal—Part I: the effect of an acetabular labral tear, repair, resection, and reconstruction on hip fluid pressurization. *Knee Surg Sports Traumatol Arthrosc* 2014; **22**: 722–9.
- Ferguson SJ, Bryant JT, Ganz R *et al*. The influence of the acetabular labrum on hip joint cartilage consolidation: a poroelastic finite element model. *J Biomech* 2000; **33**: 953–60.
- Ferguson SJ, Bryant JT, Ganz R *et al*. The acetabular labrum seal: a poroelastic finite element model. *J Biomech* 2000; **15**: 463–8.
- Groh MM, Herrera J. A comprehensive review of hip labral tears. *Curr Rev Musculoskelet Med* 2009; **2**: 105–17.
- Degen RM, O'Sullivan E, Sink EL *et al*. Psoas tunnel perforation—an unreported complication of hip arthroscopy. *J Hip Preserv Surg* 2015; **2**: 272–9.
- Degen RM, Poultides L, Mayer SW *et al*. Safety of hip anchor insertion from the midanterior and distal anterolateral portals with a straight drill guide: a cadaveric study. *Am J Sports Med* 2017; **45**: 627–35.
- Dumont GD, Money AJ, Thier ZT. Acetabular subchondral and cortical perforation during labral repair with suture anchors: influence of portal location, curved versus straight drill guides, and drill starting point. *Arthroscopy* 2019; **35**: 2349–54.
- Matsuda DK, Bharam S, White BJ *et al*. Anchor-induced chondral damage in the hip. *J Hip Preserv Surg* 2015; **2**: 56–64.
- Foster AD, Ryan J, Ellis T *et al*. Safe suture anchor insertion for anterior and posterior hip labral repair. *J Hip Preserv Surg* 2015; **2**: 170–4.
- Hernandez JD, McGrath BE. Safe angle for suture anchor insertion during acetabular labral repair. *Arthroscopy* 2008; **24**: 1390–4.
- Lertwanich P, Ejnisman L, Torry MR *et al*. Defining a safety margin for labral suture anchor insertion using the acetabular rim angle. *Am J Sports Med* 2011; **39**: 111s–6s.
- Kelly BT, Weiland DE, Schenker ML *et al*. Arthroscopic labral repair in the hip: surgical technique and review of the literature. *Arthroscopy* 2005; **21**: 1496–504.
- Murphy KP, Ross AE, Javernick MA *et al*. Repair of the adult acetabular labrum. *Arthroscopy* 2006; **22**: 567.
- Philippon MJ, Schenker ML. A new method for acetabular rim trimming and labral repair. *Clin Sports Med* 2006; **25**: 293–7.
- Gereli A, Kocaoglu B, Ulku KT *et al*. Are pelvic anatomical structures in danger during arthroscopic acetabular labral repair? Definition of safe bone depth. *Knee Surg Sports Traumatol Arthrosc* 2017; **25**: 45–9.
- Kuroda Y, Rai A, Saito M *et al*. Anatomical variation of the Psoas Valley: a scoping review. *BMC Musculoskelet Disord* 2020; **21**: 219.
- Nho SJ, Freedman RL, Federer AE *et al*. Computed tomographic analysis of curved and straight guides for placement of suture anchors for acetabular labral refixation. *Arthroscopy* 2013; **29**: 1623–7.
- Stanton M, Banffy M. Safe angle of anchor insertion for labral repair during hip arthroscopy. *Arthroscopy* 2016; **32**: 1793–7.