



Case series

Treatment of neuropathic unstable knee osteoarthritis by a condylar, rotating-hinge prosthesis with cementless pentagonal stem: a case series

Bugra Alpan^a, Melih Civan^{b,*}, Levent Eralp^c, Harzem Özger^c

^a Acibadem Mehmet Ali Aydınlar University, School of Medicine, Dept. of Orthopaedics and Traumatology, Kaysıdagi Cad. 34752 Atasehir, Istanbul, Turkey

^b Basaksehir Pine and Sakura City Hospital, Dept. of Orthopaedics and Traumatology, Basaksehir Olimpiyat Bulvarı 34480 Basaksehir, Istanbul, Turkey

^c Istanbul University, Istanbul Faculty of Medicine, Dept. of Orthopaedics and Traumatology (retired), Capa 34093 Fatih, Istanbul, Turkey



ARTICLE INFO

Keywords:

Neuropathic unstable knee
Osteoarthritis
Rotating-hinge prosthesis
Cementless pentagonal stem
Case series

ABSTRACT

Introduction and importance: Total knee arthroplasty (TKA) in the neuropathic unstable knee (NUK) setting is classically a challenging orthopedic problem due to intraoperative technical difficulties and a higher frequency of periprosthetic complications. More recently, satisfactory results have been reported using improved constraints, stems and revision-type TKA components. The study aims to present long-term results of a small case series with NUK osteoarthritis reconstructed by a condylar, semi-constrained prosthesis with a polygonal, hydroxyapatite-coated (HA-coated) press-fit stem.

Case presentation: From 2009 through 2010, three knees in three patients with advanced NUK arthropathy underwent TKAs in our institution using the PENTA® prosthesis. The average age at surgery was 44 years (32–58). The patients were followed up for a mean period of 124 months (120–128). The etiology of NUK was determined to be poliomyelitis sequela in 2 cases and spinal cord injury in one case. Functional outcomes were assessed with Knee Society (KS) Knee and Function Scores, and radiological outcomes were evaluated with ISOLS radiographic implant scores. Patients were monitored for complications clinically and radiologically.

Clinical discussion: KS knee scores improved from a mean of 12,3 (0–37) preoperatively to 71,3 (65–77) and KS function scores improved from a mean of 1,7 (0–5) preoperatively to 68,3 (55–80) at the latest follow-up. Radiological outcomes were excellent according to ISOLS scores, and no complications were observed.

Conclusion: Although this is a small case series, the significant improvement in functional scores, excellent radiological outcome, and implant survival at the end of a long follow-up period warrants TKA with a semi-constrained hinged implant in the setting of NUK. PENTA® prosthesis offers a good choice of implant with its hydroxyapatite-coated, press-fit, pentagonal stem and precisely designed rotating hinge.

1. Introduction

Neuropathic arthropathy is classically defined as a progressive degeneration of a senseless joint leading to damage and collapse of the weight-bearing surfaces due to subclinical microtrauma [1–3]. Charcot's description of the pathology implicated tertiary syphilis as the underlying cause. Many other diagnoses causing neuropathic arthropathy have subsequently been identified, including leprosy, alcoholism, syringomyelia, spinal trauma sequela, poliomyelitis, and more frequently in recent decades, diabetes mellitus (DM) [3–5]. Neuropathic unstable knee (NUK) caused by DM had been accepted as a relative contraindication to total knee arthroplasty (TKA) in the past. However, satisfactory results in these cases have been reported more recently using improved

constraints, stems and revision-type TKA components [6–8]. Surgeons are often concerned about the technical difficulties of the operation, as well as the higher frequency of reported complications, including periprosthetic joint infections, knee dislocations, and periprosthetic fractures [6].

This study aims to present late results of a small case series of end-stage NUK osteoarthritis reconstructed by a condylar, semi-constrained, prosthesis with a polygonal, hydroxyapatite-coated (HA-coated), press-fit stem. The prosthesis was actually designed as a modular reconstruction system for sarcoma patients (PENTA® TIPSAN, Izmir, Turkey) and condylar joint replacement modification was implanted in NUK patients. The results are discussed as implant survivorship at ten years, clinical and radiologic outcomes, and

* Corresponding author at: Basaksehir Pine and Sakura City Hospital, Basaksehir Olimpiyat Bulvarı, Basaksehir, Istanbul 34480, Turkey.

E-mail address: melih.civan@istanbul.edu.tr (M. Civan).

<https://doi.org/10.1016/j.ijscr.2023.108389>

Received 2 April 2023; Received in revised form 5 June 2023; Accepted 6 June 2023

Available online 14 June 2023

2210-2612/© 2023 The Authors. Published by Elsevier Ltd on behalf of IJS Publishing Group Ltd. This is an open access article under the CC BY-NC-ND license (<http://creativecommons.org/licenses/by-nc-nd/4.0/>).

complications. This case series has been reported in line with the Process 2020 Guideline [18].

2. Case presentation

2.1. Patients

From 2009 through 2010, three knees in three patients with advanced NUK arthropathy underwent TKAs in our institution using the PENTA® prosthesis. The patients were followed up for a mean period of 124 months (120–128), and the average age at surgery was 44 years (32–58). The diagnoses of NUK were confirmed with neurology consultation and were based on clinical findings, radiographs of the knees, magnetic resonance imaging of the whole spine, electromyography and laboratory tests (vitamin B12, serology for syphilis and HIV). Walking difficulty with moderate pain, significant swelling and giving-way of the knees were the common complaints in all three patients. However, the scale of pain they described was inconsistent with the radiographic appearance of their knees. Clinical examination also

revealed a full range of motion with complete ligamentous laxity. Knee extensor muscle strength was impaired in poliomyelitis patients; however, flexion is 4/5 on the motor function scale. Radiographic examination revealed considerable bone destruction, large periarticular osteophytes, synovial-chondromatosis-like loose bodies, malalignment and subluxations (Fig. 1).

NUKS's underlying causes were possible poliomyelitis (Cases 1 and 3) and paraparesia resulting from burst fracture of 12th thoracic vertebra (Case 2). All cases were non-menopausal females under 45. One of the poliomyelitis patients had a deformity correction on both the distal femur and proximal tibia aiming to neutralize the mechanical axis (Case 1). This patient presented to our institution with global instability and pain two years after this operation. The patient with vertebral burst fracture sequela (Case 2) sustained this injury 12 years prior to presenting to us. She had undergone surgical treatment for paraplegia due to T12 burst fracture within 24 h of the injury by neural decompression and spinal stabilization, but had healed with slight neurologic deficit.

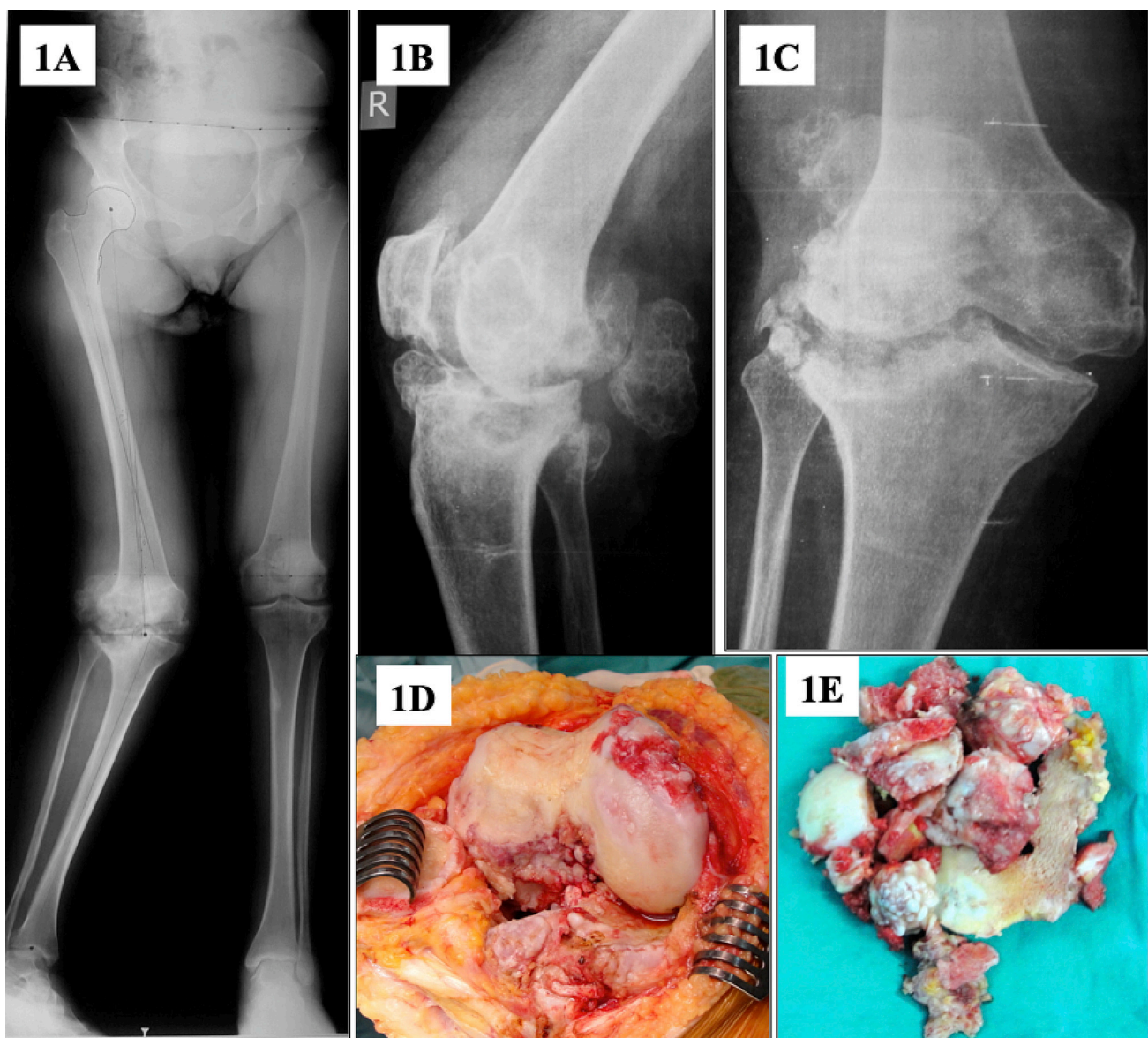


Fig. 1. Severe valgus malalignment of the right knee, extensive bone destruction in the lateral compartment, large osteophytes and loose bodies can be seen in the AP standing full-length lower extremity (1A), standard lateral knee (1B) and AP knee radiographs (1C) of Case 2 at presentation. Advanced osteoarthritic changes (1D) and abundant amount of excised osteophytes and loose bodies (1E) were documented intraoperatively.

2.2. The implant (PENTA®)

PENTA® modular extremity reconstruction system (formerly known as PENTA-MERS) is a modular prosthesis designed to reconstruct irreparable defects involving the hip, knee, shoulder and elbow joints caused by tumor resection, revision arthroplasty, unstable knees, or trauma. The implant system's design rationale and main advantages are linked to its anchorage, modularity and articulation characteristics [9].

PENTA® implant is named after its stem with "pentagonal cross-section". The stem has a slight taper towards the tip to prevent unnecessary bone loss and stress shielding. Although cemented stem options are available in the implant set, the stem is designed for particularly cementless, press-fit implantation. The stem's pentagonal cross-section aims to increase primary rotational stability while maintaining an acceptable risk of bone damage during broaching and insertion of the stem. The cementless stems are coated with hydroxyapatite to ensure secondary stability through osseointegration. The femoral condylar component has laterality due to 5 degrees of valgus and is available in 3 sizes. The tibial baseplate is uniform and also available in 3 sizes. Various femoral stem options (length: 120, 150 and 200 mm; diameter 12–22 mm; curvature: straight/anatomical) for femoral condylar component and tibial stem extensions (length: 60, 90 mm; diameter: 12–20 mm) for tibial baseplate are available. The system allows en bloc modular replacement of the distal femur and proximal tibia and replacing only the joint surfaces [9].

PENTA® knee implant has a rotational hinge mechanism, which connects the femoral and tibial components with a yoke assembly (tibial rotation piece). The hinge formed by the distal femur and the yoke

allows a 0°-130° range of motion. Two features limit maximum flexion and extension of the hinge. The first one is the corresponding stepped rotation blocks on the axle head and inside the axle socket of the femoral component, and the second feature is the bumper insert on the yoke. The yoke allows 15° of internal and external rotation of the knee through its articulation with the proximal tibia. The rotation occurs around the cylindrical yoke post, which resides unconstrained in the proximal tibia. Two features are critical in restriction of rotation. There are two projections on the convex undersurface of the yoke and corresponding grooves on the concave upper surface of the tibial insert, which is fixed to the proximal tibia. While the projections and their corresponding grooves seem to limit the rotation sharply, the non-spherical interface geometry of the undersurface of the yoke and upper surface of the tibial insert facilitate a smoother stop at the endpoints of rotation [9] (Fig. 2).

2.3. Surgical technique

All patients underwent cementless total knee arthroplasty with condylar, semi-constrained, rotating-hinged PENTA® modular replacement system by a medial parapatellar approach. All patients underwent patellar soft tissue realignment with lateral release and vastus medialis advancement. Following exposure of the joint surfaces, proper cuts were performed using the implant system's jigs. The medullary canal of the femur and tibia were reamed with flexible reamers. Appropriate-sized tibial baseplates, femoral condylar components, and intramedullary stems with fitting lengths and diameters were prepared. While the femoral stems were inserted press-fit separately and the femoral condylar components were placed onto the stems subsequently, the

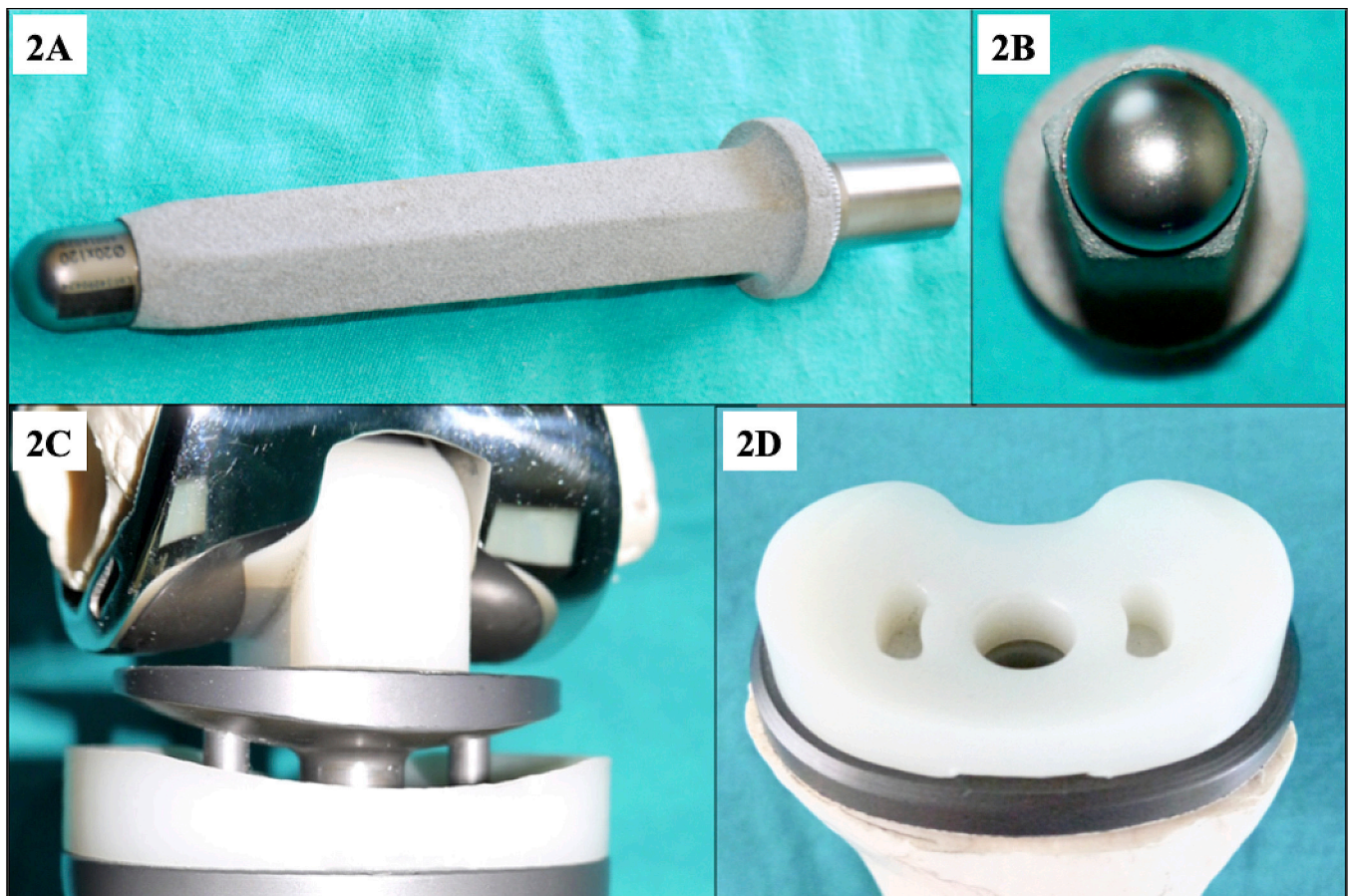


Fig. 2. The cementless pentagonal hydroxyapatite-coated stem, which gives the PENTA® implant its name is demonstrated (2A and 2B). The hinge mechanism, which is composed of the tibial insert, the tibial rotation piece and the bumper insert, is shown in distracted position (2C and 2D). The hard-stop at the end of internal and external rotation is smoothed out by the non-spherical interface geometry between the yoke and the tibial insert while the yoke underprojections sit inside the tibial insert grooves.

tibial baseplates were implanted together with their stem extensions, which were mounted outside the patient. After the implantation of anchorage components, rotating-hinge mechanism was assembled. On the first postoperative day, all patients were encouraged to start walking with weight bearing as tolerated using two crutches. Active assistive and active range-of-motion exercises were initiated at the same time. No external brace was used.

2.4. Clinical follow-up

Clinical and radiological follow-up examinations were performed every three months in the first postoperative year, six months in the 2nd year, yearly from 2nd through the fifth postoperative year and every five years after that. Knee society (KS) knee and function scores were obtained pre- and postoperatively utilizing a standard questionnaire [10].

2.5. Radiological analysis

Standard pre- and postoperative radiographs included anteroposterior (AP), lateral, merchant, stress views in both AP and lateral plane, and standing full-length lower extremity views. Instability was classified according to Mullaji [11]. In this classification: type 1 describes severe coronal plane (medial and/or lateral) instability, type 2 describes severe coronal and sagittal plane (posterior) instability and type 3 describes global instability (posterior subluxation). Because of the nature of the utilized implant, postoperative radiographs were assessed

by ISOLS radiologic implant evaluation system. The original scoring system consists of 6 parameters. Our study only analyzed interface, anchorage and implant articulation scores, excluding bone remodeling, extracortical bone bridging, and implant body scores, as they were non-applicable to this particular patient group [12].

3. Results

Knee society knee scores improved from a mean of 12,3 (0–37) preoperatively to 71,3 (65–77), and KS function scores improved from a mean of 1,7 (0–5) preoperatively to 68,3 (55–80) at the latest follow-up.

Preoperative evaluation yielded one patient with Mullaji type 1, one with type 2 (Fig. 3) and one patient with Mullaji type 3 instability. During the latest follow-up radiological examination, all patients had a physiologic alignment, no sign of instability, no radiolucent lines below the femoral condylar component and tibial baseplate and around the pentagonal stems (Fig. 4).

None of the three patients developed an aseptic or septic loosening. No superficial or deep infection, deep venous thrombosis, or persistent contractures were observed. Prosthesis survivorship after ten years was 100 % and all three patients were free of other reoperations (Table 1).

4. Discussion

Neuropathic arthropathy, attributed to neurosyphilis when first described by Charcot in the nineteenth century, is most often seen as a

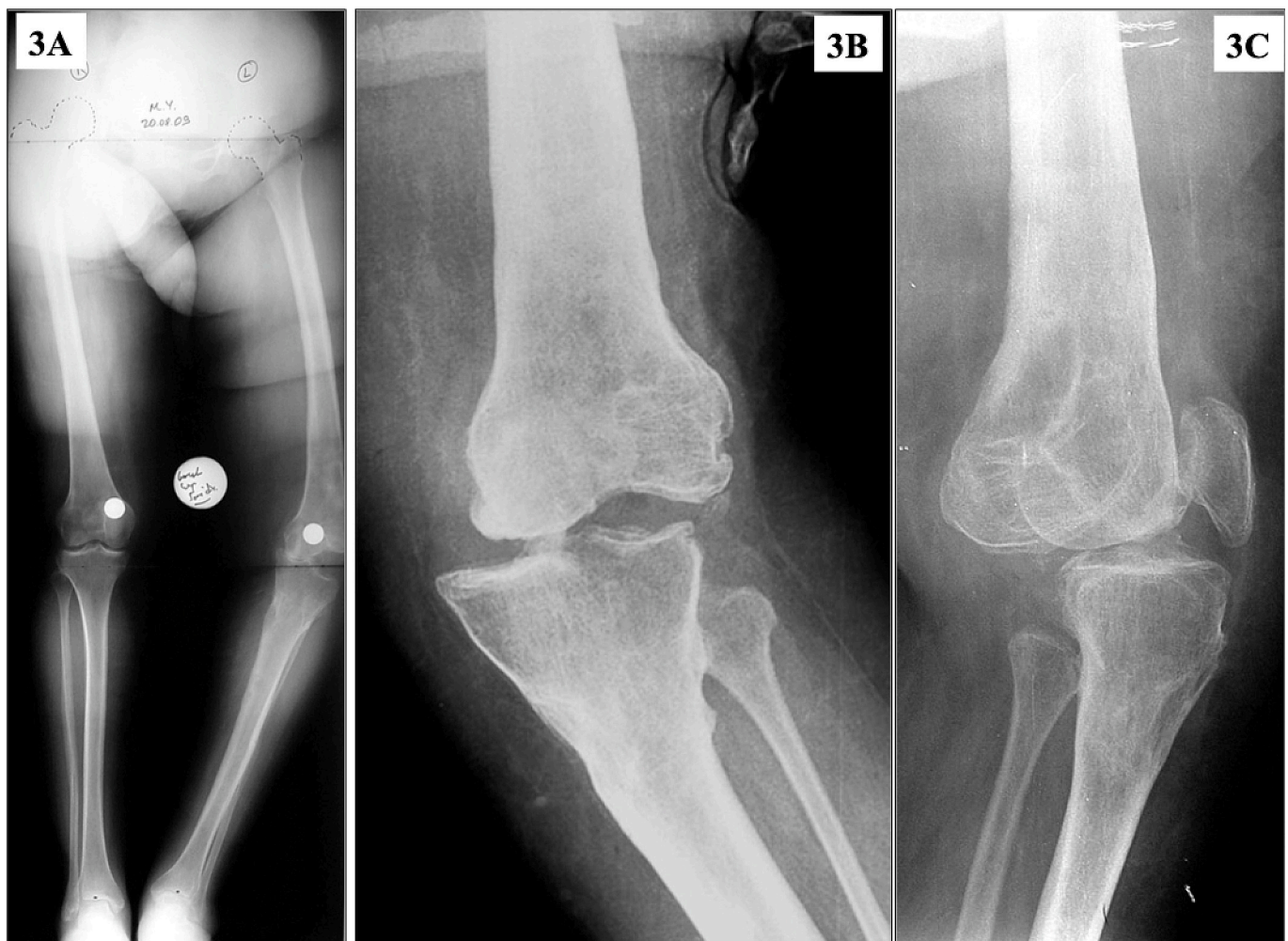


Fig. 3. AP standing full-length lower extremity (3A), standard AP (3B) and lateral radiographs (3C) of Case 1 at presentation is consistent with Mullaji type 2 instability.

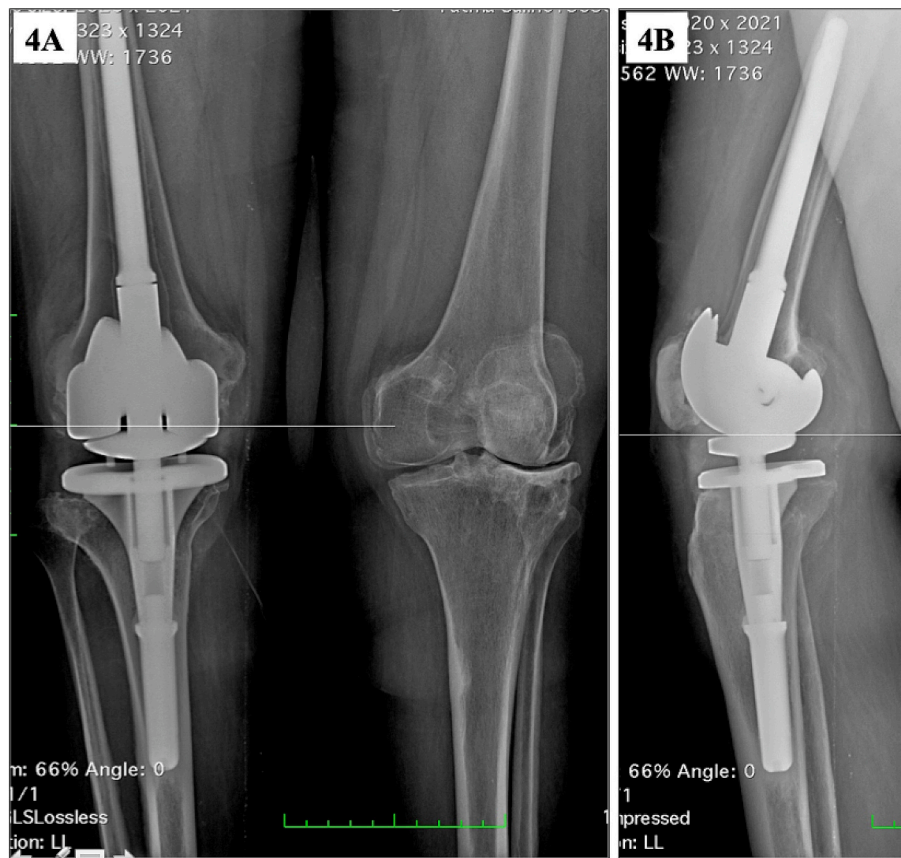


Fig. 4. AP (4A) and lateral (4B) radiographs of Case 2 at 10 years postoperatively show excellent outcome in terms of interface, anchorage and implant articulation scores.

Table 1
Summary of demographics, functional and radiological outcomes and complications.

Case No	Sex	Age	NUK ¹ Etiology	Mullaji Knee Instability Type	Preop KS ⁴ Knee Score	Preop KS Function Score	Postop KS Knee Score	Postop KS Function Score	ISOLS Radiographic Score ^a	Complication	Implant survival (%)
1	F	32	Poliomyelitis	1	0	0	77	70	EXCELLENT	None	100
2	F	42	SC injury	2	37	0	72	80	EXCELLENT	None	100
3	F	58	Poliomyelitis	3	0	5	65	55	EXCELLENT	None	100

NUK: Neuropathic Unstable Knee, SC: Spinal Cord, KS: Knee Society, ISOLS: International Society On Limb Salvage.

^a Modified ISOLS Radiographic Score (*only* interface, anchorage, implant articulation *included*).

complication of diabetes mellitus in the developed countries today [1–3]. Furthermore, the etiology of neuropathic arthropathy includes numerous other conditions, some of which are relatively rare such as poliomyelitis and spinal cord injury [3–5]. The main focus of this study was to analyze and report the outcomes of NUK arthroplasty with the PENTA knee implant in our institution, rather than reviewing all cases of NUK. The etiology for each NUK patient, who underwent arthroplasty with PENTA, has been mentioned in the “Patients and Methods” section. For all 3 cases, the diagnosis of NUK was confirmed preoperatively by neurology consultation, which included neurological examination, electromyography and whole spine MRI.

Prosthesis selection for NUK arthropathy patients remains a challenging decision, with unconstrained, condylar-constrained, rotating-hinged and even highly-constrained prostheses used in the past [13]. However, unconstrained or highly constrained components are reported unsuitable in this patient group because of high risk of aseptic loosening and periprosthetic fracture [2,6]. Some authors advocate the use of rotating-hinged prostheses with due to their intrinsic stability [1,2,6,7].

When using a constrained component, a long stem is recommended to disperse the increased bone stress [13]. Mostly cemented stems are used. The implant presented in this study has a rotating hinge and the HA-coated stems are implanted in a press-fit cementless fashion.

The literature has reported good 10-year survivorship, ranging from 51 % to 92.5 %, for rotating-hinge knee implants. Infection and aseptic loosening are the most commonly reported complications, with rates range from 9.2 % to 63 % [14,15]. The authors of this study believe that the unique stem geometry and the sophisticated rotating-hinge mechanism, which were designed to meet the demands of post-oncologic reconstructions, contribute to 100 % prosthesis survivorship at ten years in these patients. However, the small number of patients prevents drawing a significant conclusion.

The literature does not provide a clear resolution on whether to fix the stems in a cementless or cemented fashion. However, the rationale for cementless stem fixation is supported by the potential for bone integration, which is assumed to impede aseptic loosening, and the eliminated problem of removing cement remnants in case of revision

surgery. Cementless press-fit stems have been constructed in various shapes (fluted, fenestrated) and textures (grit-blasted, porous-coated, beaded, hydroxyapatite-coated) to increase osteointegration of the implant inside the medullary cavity. Pala et al. compared cemented and cementless fixation in post-oncologic reconstructions. They observed the cementless fixation group to have higher overall survival and survival to infection, whereas survival to aseptic loosening was not significantly different from the cemented group. Cemented fixation might be more appropriate in patients with bone metastases, extensive osteolytic defects, bad prognosis and elderly patients, in whom either the osteointegration is impaired or the time to osteointegration is incompatible with patient survival. On the other hand, cementless fixation is preferable in young patients with primary bone tumors [16,17]. In this study, cementless PENTA® stems resulted in excellent long-term survival. To the author's knowledge, no reported series compares cemented and cementless stems in NUK osteoarthritis patients.

The prosthesis design must be harmonious with the biomechanics to survive longer. Early fixed-hinge modular prosthesis designs failed with aseptic loosening due to physiological torsional forces acting on the anchorage sites. Rotating-hinge mechanisms were designed to match the physiological rotation of the knee through the arc of flexion and extension. However, even with the rotating-hinge designs, the hard stops at the ends of the rotation arc lead to progressive osteolysis in the interface, followed by aseptic loosening or implant breakage. The rotating-hinge mechanism of the PENTA®, as described in the "Methods" section, allows for load distribution at the ends of rotation and prevents the hard-stop phenomenon. The semi-constrained design allows excellent function with excellent knee stability, as evident by the significant improvement of KS Knee and Function Scores.

5. Conclusion

Although technically demanding and susceptible to significant complications, arthroplasty on a symptomatic NUK arthropathy patient can be beneficial. The relatively higher rate of complications and revision surgery in these patients may be avoided by observing the fundamental principles of knee arthroplasty in achieving ligamentous balancing, lower extremity alignment, and reconstruction of osteo-articular defects. Selecting implants with superior anchorage and articulation properties improve survival to aseptic loosening. PENTA® prosthesis combines these properties well through a hydroxyapatite-coated, press-fit, pentagonal stem and precisely designed rotating hinge. The limitation of this study is the small number of patients. Nevertheless, the long follow-up period favors a new selection of TKA in NUK arthropathy patients, providing outstanding results.

Consent

Written informed consent was obtained from the patient for publication of this case report and accompanying images. A copy of the written consent is available for review by the Editor-in-Chief of this journal on request.

Ethical approval

The ethical committee approval is exempt for this retrospective study at our institution (Istanbul University, Istanbul Medical School, 13/5/2020, Decision: 202005-130219). Institutional review board were obtained and available upon request. (2126351235, Chairman: Prof. Dr. Hayati Durmaz Date: 2020.05.20, Istanbul Medical Faculty, Department of Orthopedics and Traumatology)

Funding

None declared.

Author contribution

Bugra ALPAN, MD: The acquisition of the data, analysis of the data. Validation and supervision of the data. Statistical analysis.

Melih Civan, MD²: Writing of the manuscript, analysis of the data. Preparation of the manuscript to be submitted.

Levent ERALP, MD: The interpretation of the data and preparation of the methodology. Critical contribution to the intellectual content.

Harzem ÖZGER, MD: Senior author, conception and design of the study, final approval of the version to be submitted.

Guarantor

Harzem ÖZGER, Prof. MD and Levent Eralp Prof. MD are the guarantor authors of the study.

Melih Civan, MD is the corresponding author.

Research registration number

202005-130219

Acknowledgement & Funding

(-).

Conflict of interest statement

The senior author (HO) is a patent holder and non-paid consultant for the PENTA® implant (PENTA® TIPSAN, Izmir, Turkey) that is described and used in the treatment of patients in this study.

The other authors (BA, MC and LE) have none declared.

References

- [1] M.E. Tibbo, B.P. Chalmers, D.J. Berry, M.W. Pagnano, D.G. Lewallen, M.P. Abdel, Primary total knee arthroplasty in patients with neuropathic (Charcot) arthropathy: contemporary results, *J. Arthroplasty* 1–27 (2018), <https://doi.org/10.1016/j.arth.2018.04.003>.
- [2] S. Babazadeh, J.D. Stoney, K. Lim, P.F.M. Choong, Arthroplasty of a Charcot knee, *Orthop. Rev.* 2 (2) (2010) 17, <https://doi.org/10.4081/or.2010.e17>.
- [3] R.L.S. Chan, C.H. Chan, H.F. Chan, N.Y. Pan, The many facets of neuropathic arthropathy, *BJR|Open* 1 (2019) 20180039, <https://doi.org/10.1148/radiology.182.1.1727284>.
- [4] E. Gouveri, Charcot osteoarthritis in diabetes: a brief review with an emphasis on clinical practice, *WJD* 2 (2011) 59, <https://doi.org/10.4239/wjd.v2.i5.59>.
- [5] R. Gupta, A short history of neuropathic arthropathy, *Clin. Orthop. Relat. Res.* (1993) 43–49.
- [6] J. Parvizi, J. Marrs, B.F. Morrey, Total knee arthroplasty for neuropathic (Charcot) joints, *Clin. Orthop. Relat. Res.* 416 (2003) 145–150, <https://doi.org/10.1097/01.blo.0000081937.75404.ed>.
- [7] D.K. Bae, S.J. Song, K.H. Yoon, J.H. Noh, Long-term outcome of total knee arthroplasty in Charcot joint: a 10- to 22-year follow-up, *J. Arthroplast.* 24 (8) (2009) 1152, <https://doi.org/10.1016/j.arth.2009.05.003>.
- [8] Y.H. Kim, J.S. Kim, S.W. Oh, Total knee arthroplasty in neuropathic arthropathy, *J. Bone Joint Surg. Br.* 84 (2) (2002) 216–219, <https://doi.org/10.1302/0301-620x.84b2.12312>.
- [9] PENTA-MERS Surgical Technique Catalogue, TIPSAN, Izmir, Turkey, 2010.
- [10] J.N. Insall, L.D. Dorr, R.D. Scott, W.N. Scott, Rationale of the knee society clinical rating system, *Clin. Orthop. Relat. Res.* 248 (1989) 13–14.
- [11] A.B. Mullaji, G.M. Shetty, Preoperative planning, in: *Deformity Correction in Total Knee Arthroplasty*, Springer, New York, NY, 2014.
- [12] F. Langlais, B. Tomeno, Limb Salvage: Major Reconstructions in Oncologic and Nontumoral Conditions 5th International Symposium, St. Malo ISOLS-GETO, 2012.
- [13] M. Zeng, J. Xie, Y. Hu, Total knee arthroplasty in patients with Charcot joints, *Knee Surg. Sports Traumatol. Arthrosc.* 1–6 (2016), <https://doi.org/10.1007/s00167-016-4073-6>.
- [14] E.C. Rodríguez-Merchán, Total knee arthroplasty using hinge joints: indications and results, *EFORT Open Rev.* 4 (4) (2019) 121–132, <https://doi.org/10.1007/s00264-018-3982-z>.
- [15] L. Sabatini, S. Risitano, L. Rissolio, A. Bonani, F. Atzori, A. Massè, Condylar constrained system in primary total knee replacement: our experience and literature review, *Ann. Transl. Med.* 5 (6) (2017) 135, <https://doi.org/10.21037/atm.2017.03.29>.

- [16] A.M. Griffin, J.A. Parsons, A.M. Davis, R.S. Bell, J.S. Wunder, Uncemented tumor endoprostheses at the knee: root causes of failure, *Clin. Orthop. Relat. Res.* 438 (2005) 71–79.
- [17] E. Pala, A.F. Mavrogenis, A. Angelini, E.R. Henderson, G.D. Letson, P. Ruggieri, Cemented versus cementless endoprostheses for lower limb salvage surgery, *J. Balkan Union of Oncol.* 18 (2) (2013) 496–503.
- [18] R.A. Agha, C. Sohrabi, G. Mathew, T. Franchi, A. Kerwan, N. O'Neill, PROCESS Group, The PROCESS 2020 guideline: updating consensus Preferred Reporting Of CaseSeries in Surgery (PROCESS) guidelines, *Int. J. Surg.* 84 (2020) 231–235, <https://doi.org/10.1016/j.ijsu.2020.11.005>. Dec. (Epub 2020 Nov 12. PMID: 33189880).