



Letter to the Editor

Transient cortical blindness in COVID-19 pneumonia; a PRES-like syndrome: Case report



ARTICLE INFO

Keywords:

Covid-19

Neurological involvement

PRES like syndrome

Dear Editor,

The World Health Organization declared the outbreak of the 2019 novel coronavirus, in March 12th, 2020, a global pandemic after widely spreading of the epidemic COVID-19 pneumonia cases [1]. It has been reported that, in addition to the respiratory tract infection symptoms, patients can also have neurologic signs and symptoms; like acute cerebrovascular disease, polyneuritis, encephalitis and encephalopathy [2]. In this report, we describe a patient who developed bilateral reversible cortical blindness, who presented by COVID-19 related pneumonia.

A 38 years old male patient, admitted to emergency department with a history of fever for 5 days. His body temperature was 38,5 °C, blood pressure was 130/80 mmHg and oxygen saturation 98% while he was breathing ambient air. Breath sounds were normal with adventitious sounds on both sides. His chest computerised tomography (CT) scan showed multiple, multilobar, peripheral ground-glass opacifications in both lungs (Fig. 1). Laboratory tests results showed highly elevated CRP and ferritin levels with marked lymphopenia. His nasopharyngeal swab reverse transcription-PCR (RT-PCR) was positive for SARS-CoV-2. After admission, he received hydroxychloroquine (400 mg for the first day, 200 mg/day for four days), azitromicin 500 mg/day, and oseltamivir 150 mg/day combined with nasal oxygen therapy. His oxygen saturation was declined to 88% on the second day and non-invasive mechanical ventilatory support was started at intensive care unit (ICU). On the fifth day of ICU, he suddenly developed acute confusional state with agitation and his blood pressure observed to be at high levels for a few hours. Meanwhile, the patient complained about vision loss in both eyes. In his neurological examination; he was awake, but apathic and hardly obeying commands. His pupils were 2 mm and

equally reactive to light. Fundus examination was normal. His visual acuity was severely impaired on both eyes; he could only recognize waving hands and there was perception of light. His entire neurological examination was normal. Brain magnetic resonance imaging (MRI) showed bilateral, especially left occipital, frontal cortical white matter and splenium of corpus callosum T2/Fluid-attenuated inversion recovery (FLAIR) hyperintensities and diffusion restriction in diffusion weighted imaging (DWI) (Fig. 2) revealing vasogenic edema similar to posterior reversible leucoencephalopathy (PRES). Hydroxychloroquine treatment was stopped and the dexamethasone with a 24 mg/day dose is started. On second dose of corticosteroid treatment, patient was able to obey commands and his visual impairment fully recovered. In his neurocognitive assessment we determined visual agnosia which lasted in a week. The corticosteroid therapy tapered and stopped in two weeks' time. His neurological examination and neurocognitive assessment were completely normal on the tenth day. The brain MRI performed two weeks later, showed complete regression of the lesions (Fig. 3).

1. Discussion

We still don't know why focal neurological deficits may arise during SARS-CoV-2 infection. Common suggestions for pathological mechanisms are direct virus infection invasion or inflammatory factors. Recent autopsy reports have revealed that, like many viral infections SARS-CoV-2 can cause brain tissue edema and partial neuronal degeneration [3]. Infectious toxic encephalopathy is a reversible brain dysfunction syndrome caused by systemic toxemia, metabolic disorders and hypoxia during the process of acute infection [4]. In this disease, main pathological change is brain edema without evidence of inflammation on

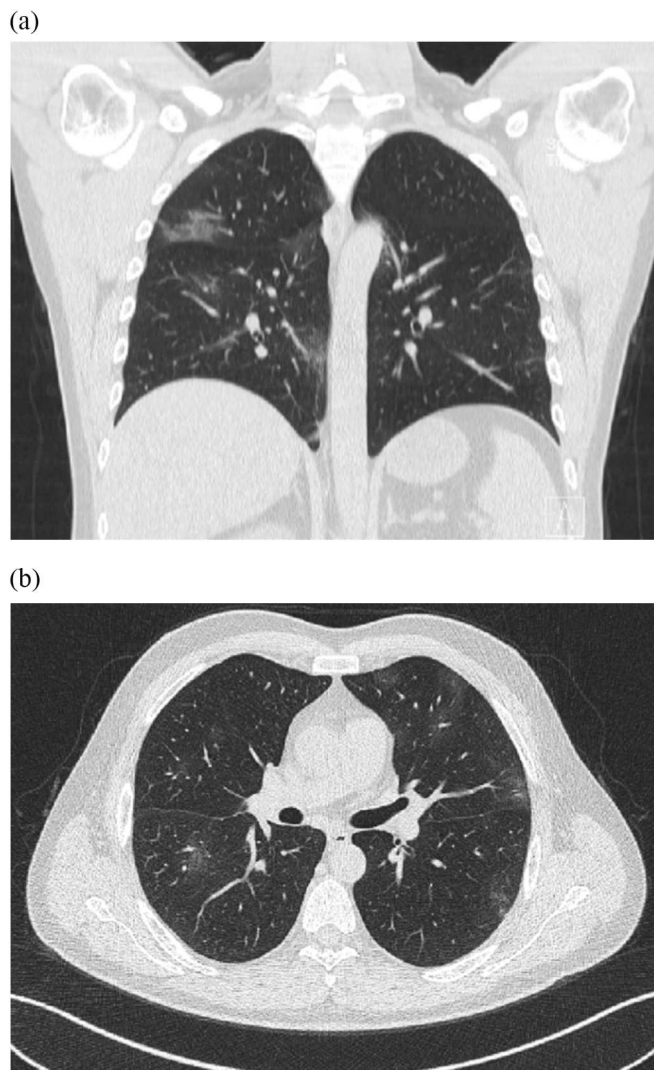


Fig. 1. Torax CT showed multiple, dominantly right patchy, peripheral, ground-glass opacities in both lungs a) coronal, b) Axial images.

cerebrospinal fluid analysis. Hypoxia in the brain causes anaerobic metabolism in the mitochondria of neurons and this leads cerebral vasodilatation, swelling of neurons, interstitial edema and obstruction of cerebral blood flow [5].

PRES is a result of a systemic inflammatory state causing endothelial dysfunction [6]. That hypothesis is supported by the observation that PRES is usually associated with a systemic inflammatory process such as sepsis, eclampsia, transplantation, and autoimmune disease [7]. Although we could not determine the exact etiology in our case, regulating the blood pressure, controlling the vasogenic edema by corticosteroid treatment and controlling the virus related pneumonia have

helped for the recovery of our patient. Unfortunately, evidences are lacking to determine which of these features were due to infectious toxic encephalopathy, and which features were specific to SARS-CoV-2 infection.

Declaration of Competing Interest

The authors declare that there are no competing interests associated with the manuscript.

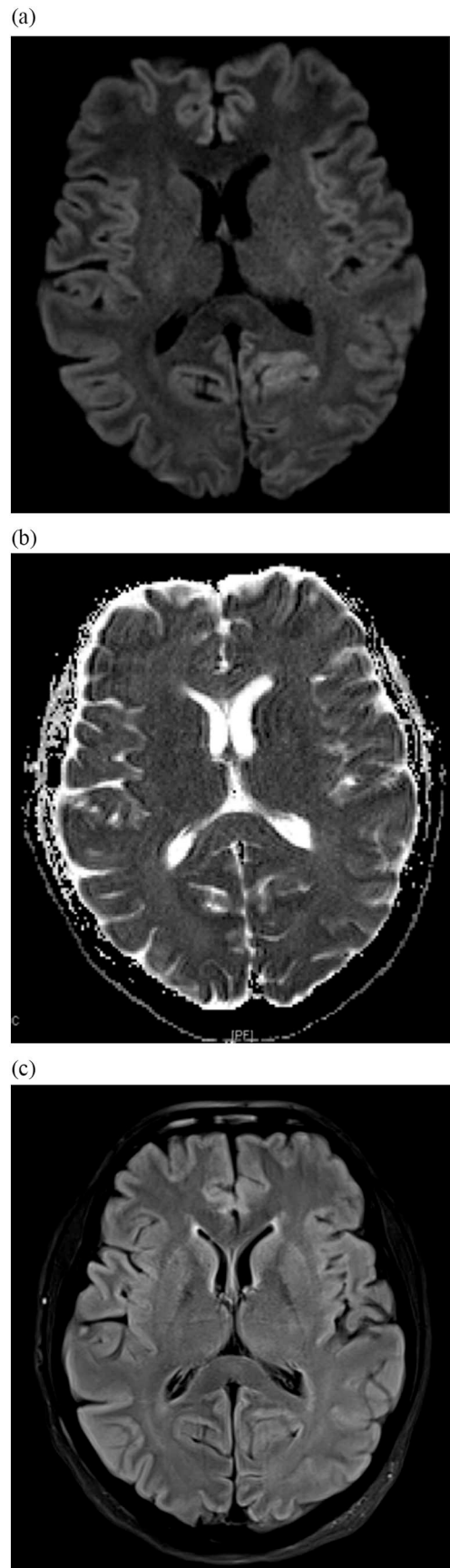
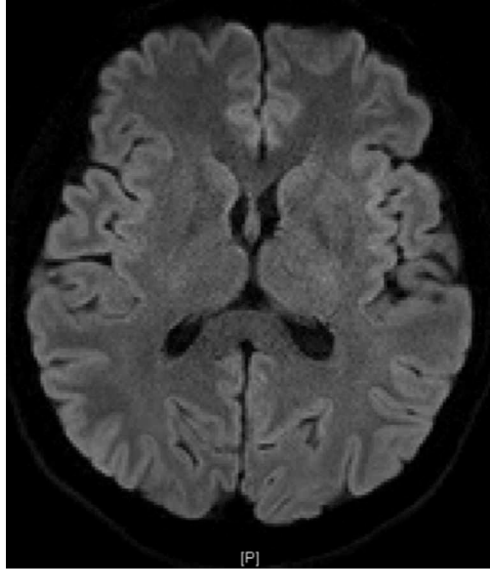
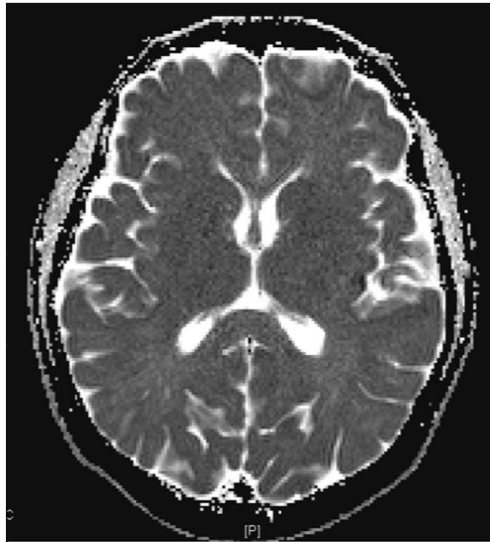


Fig. 2. Brain diffusion weighted (DWI) MRI (a) showed bilateral, especially left occipital, frontal cortical white matter and splenium of corpus callosum diffusion restriction, (b) Apparent Diffusion Coefficient (ADC) showed reduced ADC values due to vasogenic edema and FLAIR sequences (c) showed hiperintensities in the same localizations.

(a)



(b)



(c)

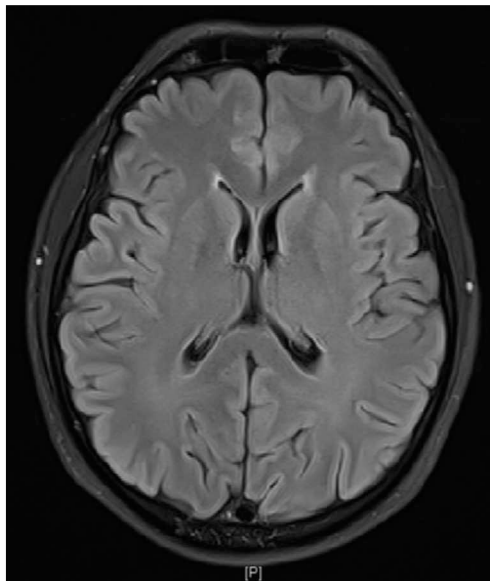


Fig. 3. On the second week of therapy DWI (a), ADC (b) and FLAIR (c) sequences showed complete regression of the lesions.

References

- [1] WHO, International Health Regulations Emergency Committee on novel coronavirus in China, 2019-nCoV, World Health Organization, Geneva, Switzerland, 2020.
- [2] Y. Wu, X. Xu, Z. Chen, J. Duan, K. Hashimoto, L. Yang, L. Cunming, C. Yang, Nervous system involvement after infection with COVID-19 and other coronaviruses, *Brain, Behavior, and Immunity* (2020), <https://doi.org/10.1016/j.bbi.2020.03.31>.
- [3] Z. Xu, L. Shi, Y. Wang, J. Zhang, L. Huang, C. Zhang, S. Liu, P. Zhao, H. Liu, L. Zhu, Y. Tai, C. Bai, T. Gao, J. Song, P. Xia, J. Dong, S. Zhao, F.S. Wang, Pathological findings of COVID-19 associated with acute respiratory distress syndrome, *Lancet Respir. Med.* 8 (2020) 420–422.
- [4] G.B. Young, Encephalopathy of infection and systemic inflammation, *J. Clin. Neurophysiol.* 30 (5) (2013) 454–461.
- [5] L. Abdenmour, C. Zeghal, M. Deme, L. Puybasset, Interaction brain-lungs, *Ann Fr Anesth Reanim* 31 (6) (2012) e101–e107.
- [6] W. Bartynski, Posterior reversible encephalopathy syndrome, part 2: controversies surrounding pathophysiology of vasogenic edema, *AJNR Am. J. Neuroradiol.* 29 (2008) 1043–1049.
- [7] M. Fisher, E. Schutzhard, Posterior reversible encephalopathy syndrome, *J. Neurol.* 264 (2017) 1608–1616.

Yildiz Kaya^{a,*}, Simay Kara^b, Canan Akinci^c, Ayse Sagduyu Kocaman^a

^a Department of Neurology, Acibadem Mehmet Ali Aydinlar University, Faculty of Medicine, Istanbul, Turkey

^b Department of Radiology, Acibadem Mehmet Ali Aydinlar University, Faculty of Medicine, Istanbul, Turkey

^c Department of Anesthesiology and Reanimation, Acibadem Fulya Hospital, Istanbul, Turkey

E-mail address: yildiz.kaya@acibadem.com (Y. Kaya).

* Corresponding author at: Department of Neurology, Acibadem Mehmet Ali Aydinlar University, Faculty of Medicine, Acibadem Fulya Hospital, Hakki Yeten St. 23, Besiktas, Istanbul, Turkey.