

CASE REPORT

A case of pulmonary alveolar microlithiasis associated with a homozygous 195 kb deletion encompassing the entire *SLC34A2* gene

Lara Stokman¹, Esther J. Nossent², Katrien Grunberg³, Lilian Meijboom⁴, Mustafa C. Yakicier⁵, Els Voorhoeve¹ & Arjan C. Houweling¹

¹Department of clinical genetics, VU University Medical Center, Amsterdam, The Netherlands

²Department of pulmonary diseases, VU University Medical Center, Amsterdam, The Netherlands

³Department of pathology, VU University Medical Center, Amsterdam, The Netherlands

⁴Department of radiology, VU University Medical Center, Amsterdam, The Netherlands

⁵Department of Molecular Biology and Genetics, Acibadem University, Istanbul, Turkey

Correspondence

Arjan C. Houweling, VU university medical center, Reception D, De Boelelaan 1118, 1081 HZ Amsterdam, Netherlands.
Tel: +3120 4440150; Fax: +31204440769;
E-mail: a.houweling@vumc.nl

Funding Information

No sources of funding were declared for this study.

Received: 8 September 2015; Revised: 25 January 2016; Accepted: 16 February 2016

Clinical Case Reports 2016; 4(4): 412–415

doi: 10.1002/ccr3.532

Key Clinical Message

With around 500 cases published worldwide, pulmonary alveolar microlithiasis is a rare disorder with an autosomal recessive pattern of inheritance. We show for the first time that homozygous deletions encompassing the entire *SCL34A2* can be associated with this rare genetic pulmonary disease.

Keywords

Homozygous whole gene deletion, pulmonary alveolar microlithiasis, *SLC34A2*, SNP array.

Introduction

We present a 20-year-old patient diagnosed with pulmonary alveolar microlithiasis (PAM). SNP array revealed a 195 kb homozygous deletion encompassing the entire *SLC34A2* gene, not reported previously in PAM. Our findings underline that deletions of this gene should be analyzed in patients with a clinical diagnosis of PAM.

Clinical Report

A 20-year-old woman without a relevant medical history was referred to the hospital for analysis after her chest X-ray suggested the presence of interstitial lung disease. She was the fourth child of consanguineous Moroccan parents. Her only complaint was mild exertional dyspnea. Physical examination revealed no clubbing and no lymphadenopathy. Fine crackles were heard over the basal lung fields. Laboratory testing revealed no abnormalities.

She did not have a history of smoking and none of her relatives had a history of pulmonary disease. She had been vaccinated with BCG and had, to her knowledge, not been in contact with people with tuberculosis. She did not have pets and had no known exposure to pulmonary allergens. She did not use any medication, homeopathic medication. Pulmonary function testing showed a restrictive pattern [Tiffeneau index 89%] with a forced vital capacity (FVC) of 2.12 L (56%), a total lung capacity (TLC) of 3.59 L (70%), and a diffusing capacity of carbon monoxide divided by the alveolar volume (DLCO/VA) of 1.91 mmol/(min *kPa*L) (103%) the lung. High-resolution computed tomography (HRCT) showed septal and subpleural linear calcifications leading to thickening of the interlobular septa with calcified intralobular nodules, most profound in the lower fields (Fig. 1). A bronchoalveolar lavage showed intracellular calcification and a transbronchial peripheral lung biopsy revealed lung tissue with numerous calcified concretions in the alveolar

space. Microbiological testing was negative, including cultures for mycobacteria. These findings confirmed the clinical diagnosis (PAM; OMIM #265100). Her parents and siblings have no medical complaints and chest X-rays of her parents were normal. Her siblings have not yet been analyzed (Fig. 2).

Genetic Analyses

Total genomic DNA was extracted from blood using standard protocols and sent to the Acibadem laboratory in Istanbul to test for mutations in the *SLC34A2* gene. DNA amplification was not successful after several attempts. MLPA testing for the *SLC34A2* gene was not available. Subsequently, an Affymetrix Cytoscan HD SNP array was performed using standard protocols. The relative DNA copy numbers at the CNV loci were determined by comparison of the normalized array signal intensity data for the proband's DNA sample against the HapMap270 reference file provided by Affymetrix, using Nexus software (from Bio-discovery, Hawthorne, California, USA) [1]. The SNP probes showed multiple regions of homozygosity, confirming consanguinity. *SLC34A2*, the causative gene for PAM, was located in a large region of homozygosity on chromosome 4. The log₂ ratio of the CNV probes covering the *SLC34A2* gene indicated a homozygous deletion with a maximal homozygously deleted region spanning ~195 kb and encompassed the entire *SLC34A2* gene. The deletion did not contain any other MIM genes (Fig. 3).

Discussion

PAM is a rare disorder in which numerous fragments (microliths) consisting of calcium phosphate gradually accumulate in the alveoli throughout the lungs [2–4].

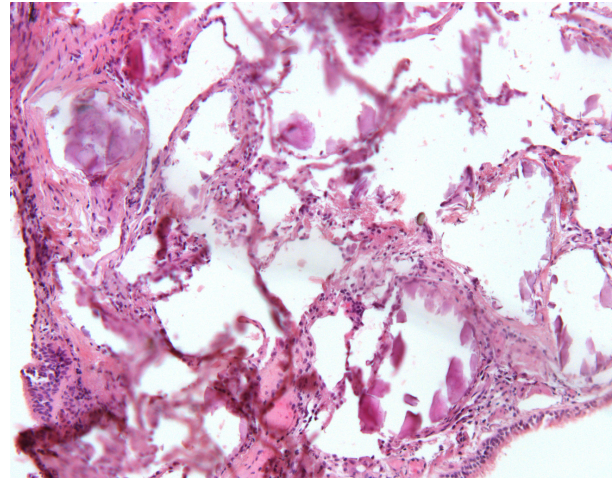


Figure 2. Transbronchial lung biopsy. Images show alveolar tissue adjacent to bronchiolar mucosa. In the alveolar spaces, many calcified concretions are seen in some areas surrounded by mild fibrotic reaction or giant cell response. Findings are consistent with pulmonary alveolar microlithiasis.

PAM is an autosomal recessive disorder caused by loss of function mutations in the gene encoding type IIb sodium-phosphate cotransporter, *SCL34A2*. The gene has 13 exons, the first of which is noncoding. The protein is involved in phosphate homeostasis [3, 5]. Homozygous loss of function mutations result in reduced phosphate reuptake by type IIb sodium phosphate transporter in the apical membrane of type II alveolar cells, resulting in calcium phosphate chelation and microlith formation resulting in a typical radiological appearance. Most patients are asymptomatic for years or even for decades after the diagnosis, which is often based on the incidental finding of a “sandstorm-appearance” on a chest X-ray. The potentially

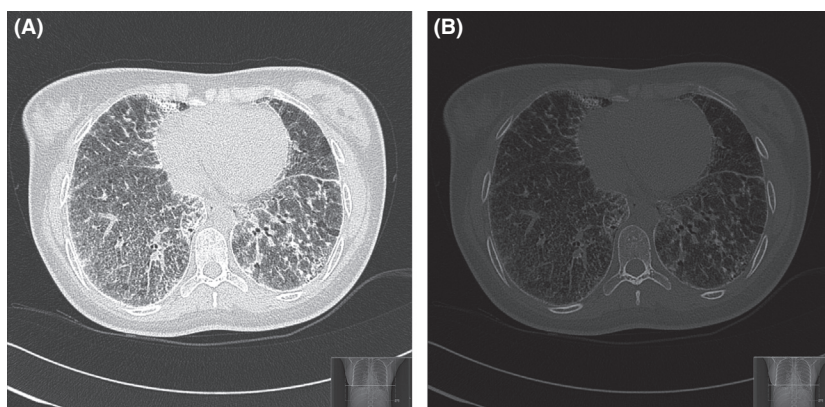


Figure 1. (A) High-resolution computed tomography (HRCT) in lung window showing thickened interlobular septal lines with fine centrilobular calcifications leading to diffuse increased density of the lung parenchyma. (B) HRCT in bone window highlighting the microlith deposition; most pronounced in the middle lobe and mediobasal segment of the right lower lobe.

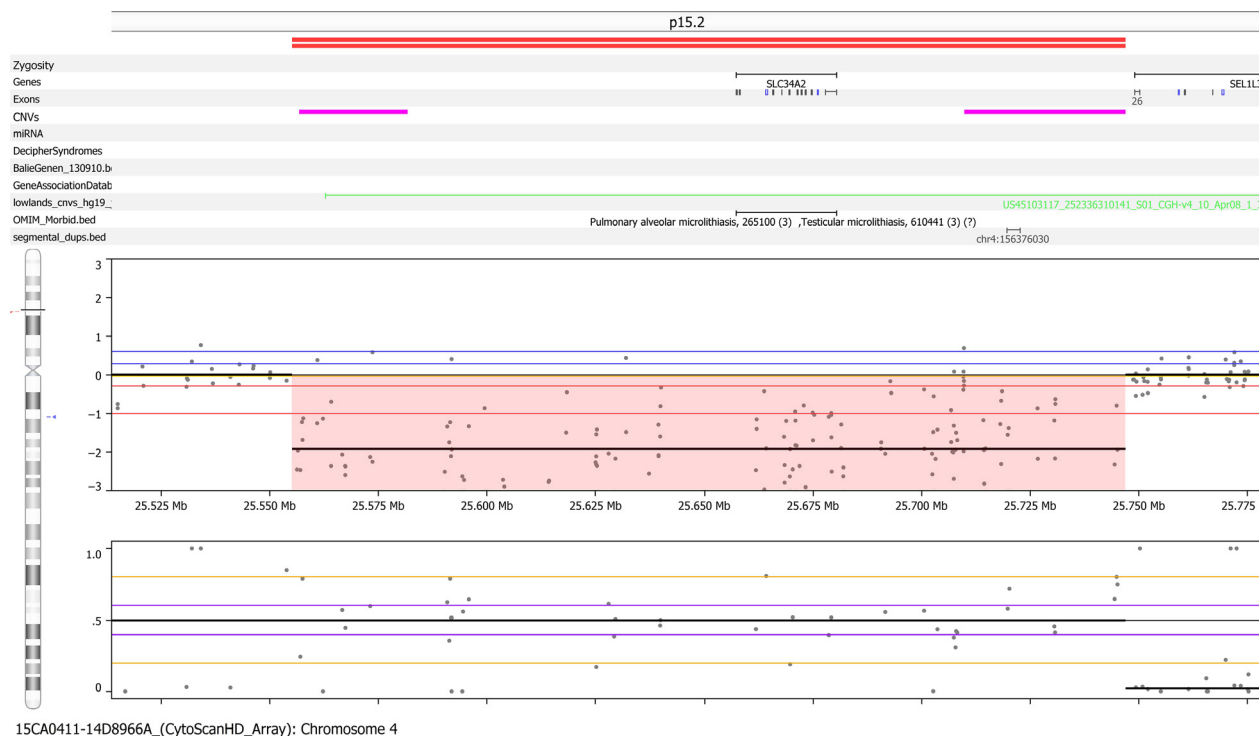


Figure 3. Homozygous deletion at 4p15.2 (double red bar) encompassing the entire *SLC34A2* gene; breakpoints deletion: arr[hg19] 4p15.2 (25,553,882-25,748,658)x0. The Log2 ratio of -1,9 (Y-axis of upper plot) is indicative for a homozygous deletion. The random noisy pattern of the SNP probes in the lower plot confirm the deletion of both alleles.

lethal disease often follows a long-term progressive course resulting in slowly deteriorating pulmonary functions. The age at clinical onset in an extensive study of 300 individuals was highly variable (5–41 years) with a great discrepancy between radiological findings and clinical symptoms [2]. The condition usually evolved over a period of 10–20 years. Only around 500 cases have been reported worldwide [4]. Currently, no clearly defined treatment options are available with exception of lung transplantation. In addition, clinical and radiological improvements were reported in two patients with PAM who were treated with bisphosphonates [6]. The reported mutations in the *SCL34A2*-gene most commonly occur in one of the exons with a predicted protein truncating effect [7]. Only five different homozygous deletions and one deletion plus insertion mutation have been described so far [5, 7, 8]. The previously reported deletions were three different single nucleotide deletions, one deletion of 186 nucleotides, and a 5.5 kb long deletion [5, 8]. We describe the first homozygous whole gene deletion detected by SNP array. This finding confirmed the clinical diagnosis of PAM in the proband and enabled genetic counseling and (presymptomatic) genetic testing in her relatives. Our study confirms the occurrence of homozygous *SCL34A2*- deletions associated with PAM, adds to the mutation spectrum by presenting the first reported

homozygous whole gene deletion and underlines the importance of including a SNP array when considering this rare disease, especially in a consanguineous pedigree.

Acknowledgment

The authors thank Dr. Blaauweegers and Dr. Cheung for their contributions to our study.

Conflict of Interest

None of the authors have conflicts of interest to declare.

References

- Bernardini, L., V. Alesi, S. Loddo, A. Novelli, I. Bottillo, A. Battaglia, et al. 2010. High-resolution SNP arrays in mental retardation diagnostics: how much do we gain? *Eur. J. Hum. Genet.* 18:178–185.
- Castellana, G., M. Gentile, R. Castellana, P. Fiorente, and V. Lamorgese. 2002. Pulmonary alveolar microlithiasis: clinical features, evolution of the phenotype, and review of the literature. *Am. J. Med. Genet.* 111:220–224.
- Ferreira Francisco, F. A., J. L. Pereira E Silva, B. Hochegger, G. Zanetti, and E. Marchiori. 2013. Pulmonary alveolar microlithiasis. State-of-the-art review. *Respir. Med.* 107:1–9.

4. Mariotta, S., A. Ricci, M. Papale, F. De Clementi, B. Sposato, L. Guidi, et al. 2004. Pulmonary alveolar microlithiasis: report on 576 cases published in the literature. *Sarcoidosis Vasc. Diffuse Lung Dis.* 21: 173–181.
5. Corut, A., A. Senyigit, S. A. Ugur, S. Altin, U. Ozcelik, H. Calisir, et al. 2006. Mutations in *SLC34A2* cause pulmonary alveolar microlithiasis and are possibly associated with testicular microlithiasis. *Am. J. Hum. Genet.* 79:650–656.
6. Ozcelik, U., E. Yalcin, M. Ariyurek, D. D. Ersoz, G. Cinel, B. Gulhan, et al. 2010. Long -term results of disodium etidronate treatment in pulmonary alveolar microlithiasis. *Pediatr. Pulmonol.* 45:514–517.
7. Yin, X., H. Wang, D. Wu, G. Zhao, J. Shao, and Y. Dai. 2013. *SLC34A2* Gene mutation of pulmonary alveolar microlithiasis: report of four cases and review of literatures. *Respir. Med.* 107:217–222.
8. Ishihara, Y., K. Hagiwara, K. Zen, Huqun, Y. Hosokawa, and A. Natsuhara. 2009. A case of pulmonary alveolar microlithiasis with an intragenetic deletion in *SLC34A2* detected by a genome-wide SNP study. *Thorax* 64:365–367. <http://thorax.bmj.com/content/64/4/365.full>