

SPONTANEOUS INTERNAL JUGULAR VEIN THROMBOSIS: A CASE REPORT

Mustafa Serinken,¹ Ozgur Karcioglu,² and Ayhan Korkmaz³

¹Department of Emergency Medicine, Pamukkale University, School of Medicine, Denizli

²Department of Emergency Medicine, Acibadem University, School of Medicine, Istanbul, and

³Department of Emergency Medicine, Denizli State Hospital, Denizli, Turkey.

Internal jugular vein thrombosis (IJVT) is an elusive vascular disease that is rarely seen, with potentially lethal complications such as sepsis and pulmonary embolism. Spontaneous IJVT is considered when no apparent predisposing cause of thrombosis is present. A previously healthy, 31-year-old woman presented to the university-based emergency department because of painless swelling in the right anterior side of her neck. Physical examination revealed a painless, soft and immobile mass in the right anterior side of her neck beneath the sternocleidomastoid muscle, without hyperemia or local heat. On ultrasonographic examination, a hyperechogenic mass was visualized around the thoracic entrance of the right internal jugular vein, which was suggestive of a thrombus. The patient was administered intravenous antibiotic and low-molecular-weight heparin followed by oral coumadin as anticoagulant therapy. Her complaints were relieved within 5 days. She was completely well after 6 months. Venous thrombosis generally results from impaired blood flow locally or systemically that leads to activation of coagulation. Primary care physicians should sustain a high index of suspicion in patients who present with undiagnosed swelling in the neck, or other signs and symptoms attributed to IJVT.

Key Words: internal jugular vein, venous thrombosis
(*Kaohsiung J Med Sci* 2010;26:679–81)

Internal jugular vein thrombosis (IJVT) is an elusive vascular disease that is rarely seen, with potentially lethal complications such as sepsis and pulmonary embolism [1]. Some precipitating conditions for IJVT include trauma, protracted intravenous (IV) catheterization, recurrent IV injections, polycythemia, neck dissection, radiotherapy, hypercoagulability as a paraneoplastic syndrome, IV drug abuse, deep neck infections, oropharyngeal infections and spontaneous occlusions [2]. The two leading causes of IJVT are iatrogenic trauma secondary to jugular vein catheterization, and repeated IV injections by drug users [1,3].

Spontaneous internal jugular vein thrombosis (SIJVT) is considered when no apparent predisposing causes of thrombosis are present within the vessel.

The present article reports a patient who was admitted to the emergency department with painless swelling in the neck, which was diagnosed sonographically as IJVT. Although almost all possible precipitating conditions were investigated and ruled out, there was no proven reason for IJVT; therefore, SIJVT was considered. The findings are discussed and compared with the published data.

CASE PRESENTATION

A previously healthy, 31-year-old woman presented to the university-based emergency department because of painless swelling in the right anterior side of her neck. She reported that her husband had first noticed



ELSEVIER

Received: Dec 21, 2009 Accepted: Feb 23, 2010
Address correspondence and reprint requests to:
Dr Mustafa Serinken, Pamukkale University
Medical School, Department of Emergency
Medicine, 20070, Denizli, Turkey.
E-mail: mserinken@hotmail.com

it 1 week before presentation. She had no previous history of trauma, malignant disease, infection, operation or IV catheterization, and had never consumed tobacco or alcohol.

Physical examination revealed a painless, soft and immobile mass in the right anterior side of her neck, beneath the sternocleidomastoid muscle. The mass was not associated with hyperemia or local heat (Figure 1). Oropharyngeal examination was unremarkable. There were no palpable cervical, axillary or inguinal lymph nodes. Examination of other systems were also normal.

Ultrasonography revealed a hyperechogenic mass around the thoracic entrance of the right internal jugular vein, which was suggestive of a thrombus (Figures 2A and 2B). The blood flow was not demonstrated by



Figure 1. Soft and immobile mass in the right anterior side of the patient's neck.

Doppler ultrasonography. The patient was diagnosed with IJVT and admitted to the hospital. Computed tomography (CT) images demonstrated a 9-cm thrombus in the internal jugular vein and cervical soft tissues were intact.

Laboratory investigations revealed a white blood cell count of $10,600/\mu\text{L}$; hemoglobin, 13.2 g/dL ; red blood cell count, $4.01 \times 10^6/\text{mL}$; platelet count, $282 \times 10^3/\text{mL}$; prothrombin time, 12.9 seconds; partial thromboplastin time, 24.6 seconds; erythrocyte sedimentation rate, 21 (0–30) mm/hr; alkaline phosphatase, 740 U/L; aspartate aminotransferase, 65 U/L; alanine aminotransferase, 89 U/L; lactate dehydrogenase, 611 U/L; creatine kinase MB isoenzyme, 35 U/L; γ glutamyl transferase, 365 U/L; free tri-iodothyronine, 3.6 pg/mL; free thyroxine, 1.02 pg/mL; and thyroid stimulating hormone, $1.48\ \mu\text{U/mL}$.

The patient was administered IV ampicillin sulbactam (3 g per day) and subcutaneous low-molecular-weight heparin (5,000 IU twice daily), followed by oral coumadin as anticoagulant therapy. The patient left the hospital against medical advice and referred herself to another institution. Further studies to determine head and neck malignancies and metastatic tumors (ultrasound and multislice CT) disclosed that there was no malignancy in the involved area. No finding suggestive of a hypercoagulable state secondary to deficiency of factor V Leiden, protein C, protein S, or antithrombin III was noted. Likewise, rheumatoid factor, C-reactive protein, antinuclear antibody, extractable nuclear antigen and ribonucleic protein were negative. Her complaints waned within 5 days, and she was completely well at a follow-up visit after 6 months.

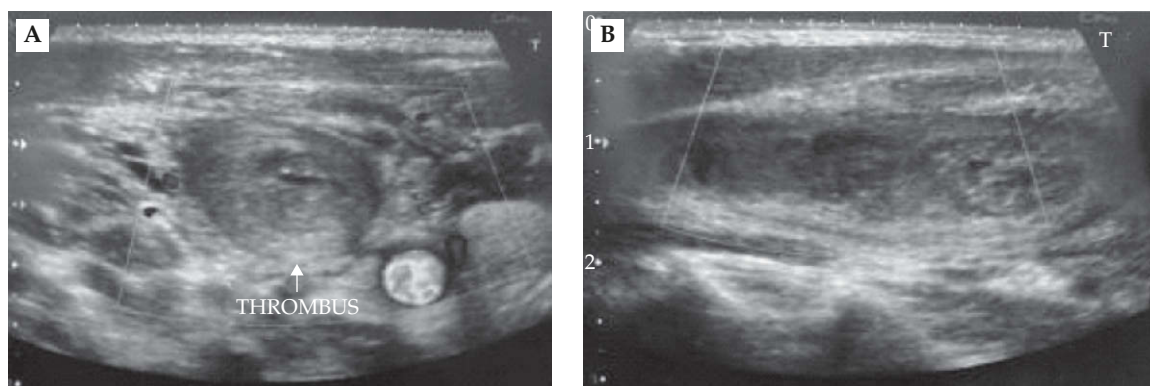


Figure 2. (A) Hyperechogenic mass around the thoracic entrance to the right internal jugular vein. The image is consistent with a thrombus. (B) Vertical view of the thrombus.

DISCUSSION

Clinical presentation of IJVT is often subtle and easy to miss. Some patients do not complain of pain or swelling in the neck, and the vein is not palpable in many patients [4]. Fever, leukocytosis, cervical pain and neck swelling are the most common manifestations in nearly 80% of patients [4]. Cord sign, sepsis syndrome and pleuropulmonary complications are also encountered in less than half of the patients, and superior vena cava syndrome can be seen in around 10% of patients.

The present patient was admitted because of swelling in the right anterior side of her neck, which was noticed by chance. The mass was painless and did not limit the range of neck motion. There was no cellulitis, tenderness or inflammation associated with the mass. She was afebrile with no leukocytosis.

Venous thrombosis generally results from impaired local or systemic blood flow that leads to activation of coagulation. Virchow was the first person to describe the so-called "classic triad" that predisposes to intravascular thrombosis. The constellation includes, but is not limited to, blood vessel injury, blood flow stasis, and a hypercoagulable state [4]. The present patient had no history of trauma and no clear hypercoagulable state secondary to deficiency of factor V Leiden, protein C, protein S, or antithrombin III. The patient also had not reported any radiotherapy. In brief, there was no identifiable cause or precipitating factor in her medical history, physical examination or laboratory investigations to lead to IJVT.

Lemierre syndrome is a well-known, nonetheless rarely identified, cause of IJVT that was first described in 1936. This syndrome is characterized by IJVT after oropharyngeal infection, and septic thrombosis associated with bacteremia is the norm [2]. Although the incidence of Lemierre syndrome has fallen significantly due to the liberal use of antibiotics, it still occurs especially in patients with low socioeconomic status [4]. The present patient had no sign of infection on examination or in her medical history. The only positive sign was a palpable swelling in the anterior neck. Lemierre syndrome can be associated with serious complications such as sepsis and pulmonary embolism [5]. As the patient has been healthy in the 6 months after illness, Lemierre syndrome can be ruled out.

Malignant neoplasms can also be the underlying factor in patients with IJVT, and these can be diagnosed or ruled out by elaborate investigations. The present

patient was evaluated thoroughly for features that were indicative of cancer, without any positive finding.

Although the diagnosis of IJVT can be established with ultrasonography, contrast-enhanced CT and magnetic resonance imaging, ultrasonography is the first imaging modality of choice for primary care and emergency physicians [2,4]. Ultrasonography is a safe, non-invasive, portable, and widely available test. Ultrasonographic findings of IJVT include a dilated and incompressible vein, together with intraluminal clotting in late presentation [4]. Doppler ultrasonography can be useful for detecting flow changes secondary to thrombus during the acute phase of clot formation. Some clinicians advocate CT scanning with IV contrast as the investigation of choice for suspected IJVT. CT images can also help differentiate the thrombus from deep neck abscesses and/or lymph nodes with central necrosis [4].

The outcome is generally favorable with similar morbidity and mortality to subclavian and axillary vein thrombosis. If systemic anticoagulation is administered, pulmonary embolism is seen in <1% of the patients with isolated IJVT [6]. These patients usually have concomitant multisystem diseases; therefore, the contribution to mortality by the thrombus itself is difficult to determine.

In conclusion, SIJVT is rare and has potentially fatal complications. Primary care physicians should sustain a high index of suspicion in patients who present with undiagnosed swelling in the neck, or other signs and symptoms attributed to IJVT.

REFERENCES

1. Ball E, Morris-Stiff G, Coxon M, et al. Internal jugular vein thrombosis in a warfarinised patient: a case report. *J Med Case Reports* 2007;20:184.
2. Gormus N, Durgut K, Ozergin U, et al. Lemierre's syndrome associated with septic pulmonary embolism: a case report. *Ann Vasc Surg* 2004;18:243–5.
3. Chowdhury K, Bloom J, Black MJ, et al. Spontaneous and nonspontaneous internal jugular vein thrombosis. *Head Neck* 1990;12:168–73.
4. Mueller DK. *Internal Jugular Vein Thrombosis*. Available at: <http://emedicine.medscape.com/article/461577-overview>. Last updated: September 21, 2009 [Date accessed: December 20, 2009]
5. David H. A 21-year-old man with fever and abdominal pain after recent peritonsillar abscess drainage. *Am J Emerg Med* 2009;27:515.e3–4.
6. Ascher E, Salles-Cunha S, Hingorani A. Morbidity and mortality associated with internal jugular vein thromboses. *Vasc Endovascular Surg* 2005;39:335–9.