

# Treatment of Crush Degloving Injury of the Hand with Totally Avulsed Thumb

Altug Altinkaya, Anil Demiröz<sup>1</sup>, Hakan Arslan<sup>1</sup>, Müge Anil Küçüksucu<sup>1</sup>

Department of Plastic, Reconstructive and Aesthetic Surgery, School of Medicine, Acibadem University, <sup>1</sup>Department of Plastic, Reconstructive and Aesthetic Surgery, Cerrahpasa School of Medicine, Istanbul University, Istanbul, Turkey

## Abstract

Avulsion injuries of the upper extremities are challenging injuries for microsurgeons, and almost always crush and degloving components are present. Due to the severe damage to the neurovascular structures, microsurgical treatment options are quite difficult, but technical advances in microsurgery have resulted in increases in the possibilities of success in crush-avulsion type replantation. Good functional outcomes can be obtained with successful replantation in these cases. In this case report, we present a successful replantation of the totally degloved thumb, the result of a crush-avulsion injury caused by silicone molding machine.

**Keywords:** Avulsion, crush, replantation, thumb

## INTRODUCTION

Avulsion injuries of the upper extremities are challenging injuries for microsurgeons, and almost always crush and degloving components are present. Replantation in this type of injuries is often considered difficult. Currently, replantation indications are accepted as multiple digit amputations, thumb amputations, whole hand or transmetacarpal hand amputations, and all amputations in children.<sup>[1]</sup>

First successful replantation of the thumb was reported in 1968 by Komatsu and Tamai.<sup>[2]</sup> Thumb amputations have a different significance compared to other amputations. The thumb is responsible for 40% of the hand functions, and therefore replantation should be attempted as the first option regardless of the injury type.<sup>[3]</sup>

## CASE REPORT

A 30-year-old male patient was admitted in our hospital emergency department suffering a silicone molding machine injury to his right hand. Skin was degloved from the level of the first carpometacarpal joint to the third web space on the dorsal side and from the level of the first carpometacarpal joint to the second proximal interphalangeal joint on the palmar side [Figure 1]. The thumb was avulsed at the interphalangeal joint level, pale in color, and had no

circulation [Figure 2]. The digital nerves and arteries were avulsed at the metacarpophalangeal joint level. The extensor pollicis longus tendon was avulsed at the interphalangeal joint level; the continuity of flexor pollicis longus tendon was preserved. A displaced shaft fracture was present in the fifth middle phalanx.

The patient was taken to the operating room. Ischemia time was approximately 3 h. Operation was performed under general anesthesia. Thumb was fixed with two axial Kirschner wires. The distal part of ulnar digital artery was dissected. Because the proximal part of the ulnar digital artery was severely damaged, distal end of ulnar digital artery was anastomosed to the vein graft that was taken from patient's distal forearm. The proximal part of the vein graft was anastomosed to the dorsal metacarpal artery. After anastomosis, perfusion to the thumb was established. In the degloved side of the skin, two dorsal veins' coursing toward the thumb and the first web space were dissected and anastomosed to their proximal cut ends. Digital nerves

**Address for correspondence:** Dr. Altug Altinkaya, Department of Plastic, Reconstructive and Aesthetic Surgery, School of Medicine, Acibadem University, Istanbul, Turkey. E-mail: altugaltinkaya@yahoo.com

### Access this article online

#### Quick Response Code:



**Website:**  
<http://www.turkjplastsurg.org>

**DOI:**  
10.4103/tjps.tjps\_11\_18

This is an open access article distributed under the terms of the Creative Commons Attribution-NonCommercial-ShareAlike 3.0 License, which allows others to remix, tweak, and build upon the work non-commercially, as long as the author is credited and the new creations are licensed under the identical terms.

**For reprints contact:** reprints@medknow.com

**How to cite this article:** Altinkaya A, Demiröz A, Arslan H, Küçüksucu MA. Treatment of crush degloving injury of the hand with totally avulsed thumb. Turk J Plast Surg 2018;26:29-31.

were easily located, and avulsed segments were debrided. After debridement, the medial antebrachial cutaneous nerve was harvested as a nerve graft and used for repair. Middle phalanx fracture of the fifth finger was fixed with Kirschner wire. After adaptation of the skin, dorsal defect from the third web space to the first carpometacarpal joint was reconstructed with a split-thickness skin graft [Figure 3]. Split-thickness graft was preferred to minimize graft loss complications.

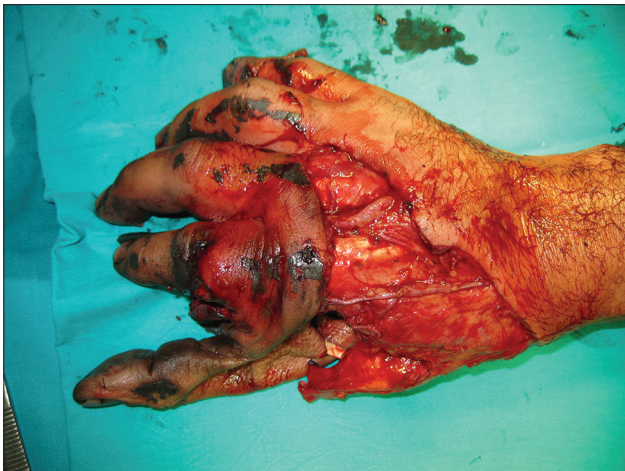Postoperatively, anticoagulation and prophylactic antibiotherapy were given to the patient. The thumb healed uneventfully. Sutures were removed in a postoperative 2<sup>nd</sup> week and Kirschner wires were removed after 1 month. At 6<sup>th</sup> month, movement in the interphalangeal joint was poor, but opposition and grasping were satisfactory [Figures 4 and 5]. He could open locked doors without help and use his hand for daily activities without restriction.

The latest amendments to the Helsinki Declaration were applied in accordance with the procedure, and the patient's consent has been obtained.

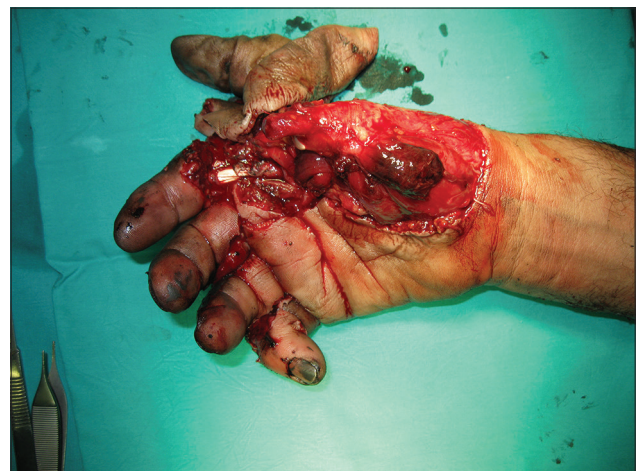## DISCUSSION

In the treatment of avulsion injuries, appropriate surgical debridement is the first step. Arterial gap could be a problem after debridement, and many methods such as arterial transposition or venous graft applications have been described in the literature.<sup>[4,5]</sup> First dorsal metacarpal artery arises directly from the radial artery between the base of thumb and the index metacarpal, then divides into branches. As in this case, if the proximal part of thumb digital artery could not be used, main trunk of the first dorsal metacarpal artery can easily be anastomosed with the distal part of thumb digital artery through the vein graft.

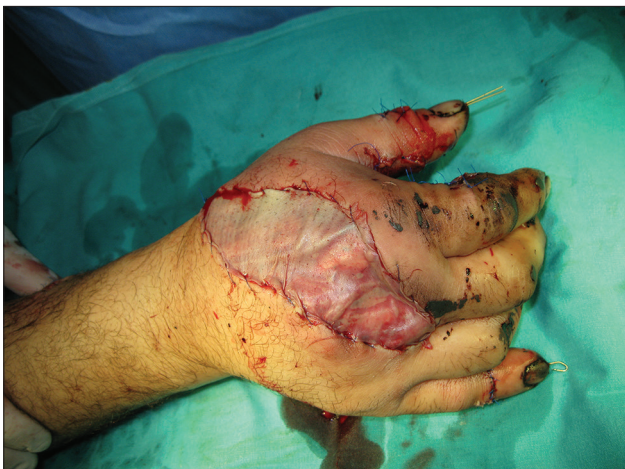Due to severe damage to the neurovascular structures, microsurgical treatment options are quite difficult in avulsion-type finger injuries. In the past, amputation, local pedicled flap, abdominal flaps, and many other treatment options have been proposed in these type injuries.<sup>[6,7]</sup> Functional and cosmetic results in all of these treatment options are inadequate. Therefore, in the treatment of such injuries, microsurgical treatment should be considered as a first choice, and in cases which microsurgery is not possible, other treatment options should be considered.<sup>[8]</sup>



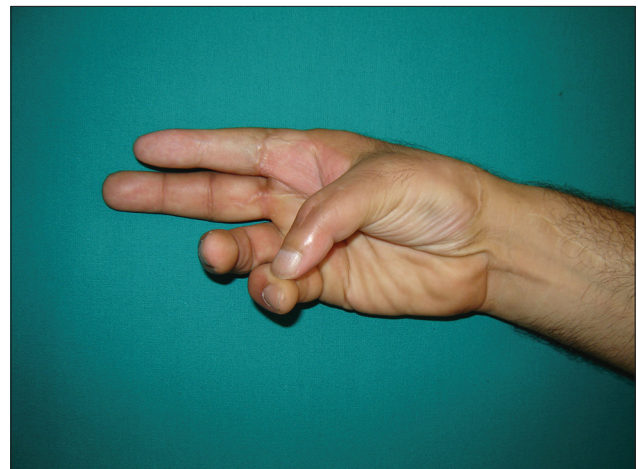
**Figure 1:** Preoperative - dorsal view of the hand and the thumb stump



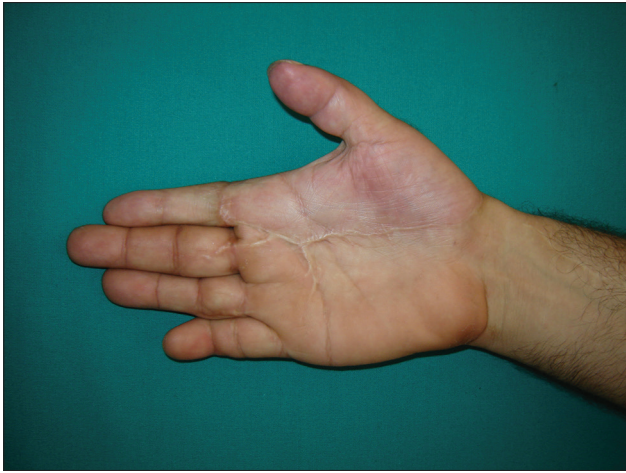
**Figure 2:** Preoperative - palmar view of the hand and the thumb stump



**Figure 3:** Immediate postoperative view of the hand



**Figure 4:** Postoperative 6 months – opposition



**Figure 5:** Postoperative 6 months – dorsal view of the hand

## CONCLUSION

Given the indispensable functions of the thumb, replantation should always be considered as the first option regardless of the severity of the injury.

## Declaration of patient consent

The authors certify that they have obtained all appropriate patient consent forms. In the form the patient(s) has/have given his/her/their consent for his/her/their images and other

clinical information to be reported in the journal. The patients understand that their names and initials will not be published and due efforts will be made to conceal their identity, but anonymity cannot be guaranteed.

## Financial support and sponsorship

Nil.

## Conflicts of interest

There are no conflicts of interest.

## REFERENCES

1. Barbary S, Dap F, Dautel G. Finger replantation: Surgical technique and indications. *Chir Main* 2013;32:363-72.
2. Komatsu S, Tamai S. Successful replantation of a completely cut-off thumb. *Plastic Reconstr Surg* 1968;42:374-7.
3. Sharma S, Lin S, Panozzo A, Tepper R, Friedman D. Thumb replantation: A retrospective review of 103 cases. *Ann Plast Surg* 2005;55:352-6.
4. Wang X, Zhang P, Zhou Y. Replantation of a circumferentially degloved ring finger by venous arterializations. *Indian J Orthop* 2013;47:422-4.
5. Dodakundi C, Hattori Y, Doi K. First dorsal metacarpal artery adiposofascial flap for venous conduit and soft tissue cover in an avulsed thumb: Case report. *J Reconstr Microsurg* 2012;28:297-300.
6. Kleinman WB, Dustman JA. Preservation of function following complete degloving injuries to the hand: Use of simultaneous groin flap, random abdominal flap, and partial-thickness skin graft. *J Hand Surg Am* 1981;6:82-9.
7. McGeorge DD, Stilwell JH. The management of the complete ring avulsion injury. *J Hand Surg Br* 1991;16:413-4.
8. Cho SH, Bahar-Moni AS, Park HC. Thumb replantation using the superficial palmar branch of the radial artery. *J Hand Microsurg* 2016;8:106-8.