

## Trauma and Reconstruction

# Urogenital and Rectal Multisystem Organ Injury After Detonation of an Explosive Substance in the Rectum of a Schizophrenic Man<sup>☆</sup>



Ali E. Zumurutbas<sup>a,\*</sup>, Aykut Baser<sup>a</sup>, Cenk I. Acar<sup>b</sup>, Yusuf Ozlulderden<sup>a</sup>, Aysegul Okutan<sup>c</sup>, Umit Y. Sahin<sup>c</sup>, Zafer Aybek<sup>a</sup>

<sup>a</sup> Department of Urology, Pamukkale University School of Medicine, Denizli, Turkey

<sup>b</sup> Department of Urology, Acibadem University School of Medicine, Istanbul, Turkey

<sup>c</sup> Department of General Surgery, Denizli State Hospital, Ministry of Health, Denizli, Turkey

## ARTICLE INFO

## Article history:

Received 4 February 2014

Accepted 6 February 2014

## Keywords:

Genitourinary trauma

Rectal trauma

Bladder

Urethral reconstruction

## ABSTRACT

Penetrating injuries are caused by the injury of perineal area with gun or stab wounds, which may cause complex injuries or multiple organ injuries. Infections, bleeding, necrotizing fasciitis, ureterocutaneous fistulas, diverticulum, abscesses, narrowing, and incontinence may arise after urethral injuries. Although there are several case reports of urogenital system traumas in the literature, this case reports a schizophrenic patient who had a multisystem genitourinary and rectal trauma after self-detonation of an explosive in the rectum and managed with reconstructive surgery without any postoperative complications. Lower urinary tract anatomy was preserved and full continence was achieved after the surgical procedure.

© 2014 The Authors. Published by Elsevier Inc. All rights reserved.

## Introduction

Trauma incidences rise in parallel with the improvements in technology. Liability of the urogenital system after emergency traumas is 10%.<sup>1</sup> Traumas of urogenital system come up in 2 ways: blunt and penetrating. Although the blunt traumas are accounted for most (90%–95%), penetrating traumas require more emergent interventions. Another site where traumas are commonly seen is the urethra (especially the posterior area) of the male sex. Blunt traumas cause >90% urethral injuries. Although penetrating injuries are caused by the injury of the perineal area with gun or stab wounds, complex injuries or multiple organ injuries may be originated from either penetrating or blunt wounds. Although there are several case reports of urogenital system traumas in the literature, this case is a multisystem-trauma patient in whom the urinary anatomy was preserved and full continence was achieved without any complications after the surgical procedure.

## Case presentation

A 35-year-old man was admitted to the emergency department of our hospital for rectal injury. He was referred after an emergency operation at a secondary care center, which included rectal and anal debridement and colostomy.

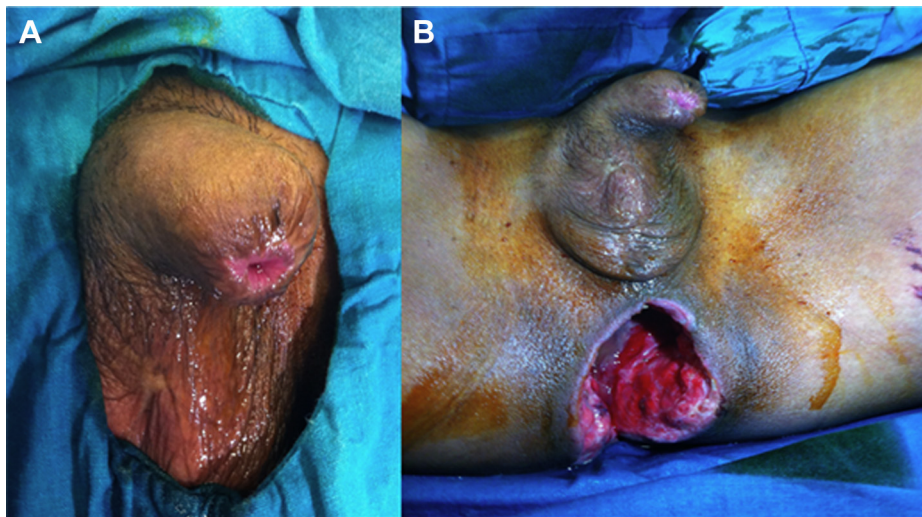
His medical history revealed the diagnosis of schizophrenia for 15 years and the history of previous self-mutilation, including multiple skin incisions and amputation of his testicles and glans penis (Fig. 1A). A day before, he inserted a dynamite-like small explosive into his rectum and fired it. Because the anal and perineal regions were totally crashed and physical examination revealed necrotic areas at anal sphincter, which extends 15 cm proximally, a foreign body was found in the colon, which was thought to be a sparkler, after wide debridement, Hartmann's colostomy was performed (Fig. 1B). After the initial operation, he was referred to our hospital for genitourinary reconstruction. In our initial examination, he had a colostomy and a large hole with a diameter of 10 cm in his anal region. His routine laboratory examinations were normal and computed tomography ruled out any further injuries in the abdominopelvic region (Fig. 2).

Urethrocystoscopy was performed under general anesthesia (Fig. 3). Large defects in the prostatic urethra and bladder neck were observed. For open reconstruction, previous suprapubic midline incision was reopened. The bladder was incised from the midline. Four 2/0 monofilament absorbable sutures were passed from the

<sup>☆</sup> This is an open access article under the CC BY-NC-ND license (<http://creativecommons.org/licenses/by-nc-nd/3.0/>).

\* Corresponding author. Tel.: +90-532-7898961; fax: +90-258-2118732.

E-mail address: [aliumrut@yahoo.com](mailto:aliumrut@yahoo.com) (A.E. Zumurutbas).



**Figure 1.** (A) Self-amputation of glans penis. (B) Initial presentation of the patient with his rectum operated (debridement and colostomy).

posterior urethra with the help of a bougie at 3-, 5-, 7-, and 9-o'clock positions. Before passing these sutures from the bladder neck, necrotic prostatic tissues at the posterior site were debrided and posterior reconstruction was completed. Then, urethral anastomosis was completed by passing each suture from the bladder neck at relevant positions. A cystostomy catheter was inserted. Distal part of the sigmoid colon and rectum, which was left in previous emergency surgery, was excised, and the large hole in the anal region was reconstructed and closed in 3 layers after the insertion of a silicone drain and a suction drain.

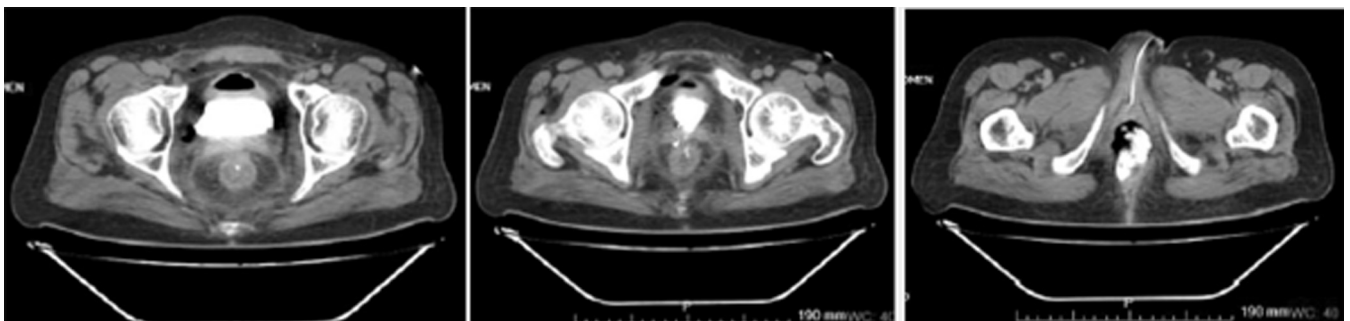
Postoperative course was uneventful and drains were removed at fifth and seventh postoperative days, respectively. The Foley catheter was removed at third postoperative week, and cystostomy was left intact for any further problem such as urinary retention or urinary fistula. After the removal of the Foley catheter, urination of the patient was normal. Two days later, he was admitted with urethral pain and a significant decrease in his flow rate. A urethrography was performed, which showed a tiny extravasation in posterior urethra. A urethral catheter was inserted over a guide-wire, which was left for another 3 weeks. After the removal of catheter, urethrography showed no extravasation, and urination of the patient was normal without any lower urinary tract symptoms.

## Discussion

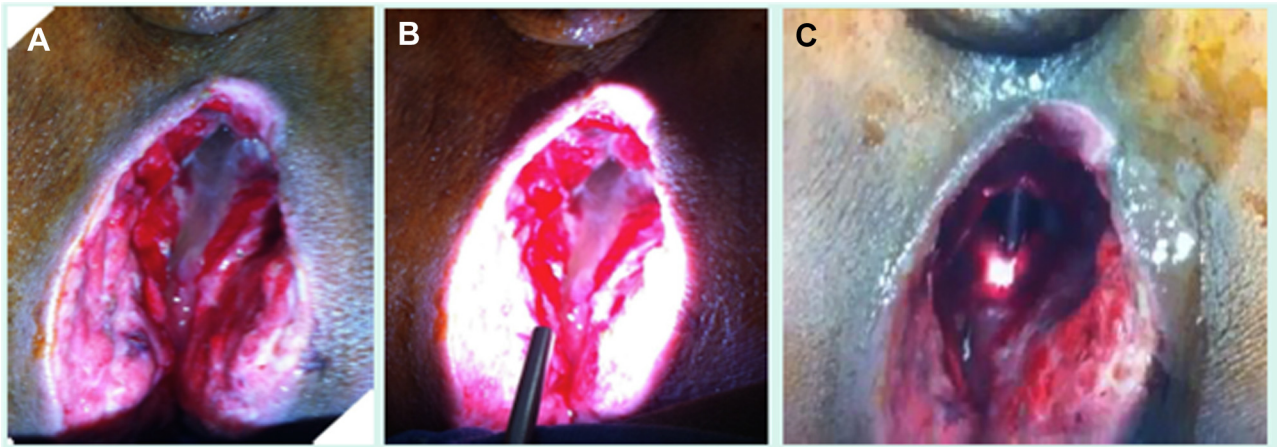
Injuries of the perianal area with explosive substances rarely occur. Standard treatment of the rectal injuries includes

perioperative antibiotics, colostomy, and drainage. Although this method serves optimally in isolated rectal traumas, it is inadequate for combined rectal and urogenital traumas. In this kind of traumas, management is not easy and complication rates are high. In our case, we primarily repaired the prostatic remnants, urethra, and bladder after rectal debridement and colostomy. Complications in isolated urethral traumas are erectile dysfunction (82%), urinary incontinence (4%), and recurrent stenosis (5%–15%).<sup>2</sup> Because our patient had psychiatric issues and the history of self-mutilation, we were not able to evaluate erectile dysfunction; however, during the follow-up we did not detect any problems regarding incontinence and obstruction.

Retrograde cystography is the most sensitive radiologic imaging method to diagnose bladder injuries. Cystographies must be taken anteroposteriorly and obliquely and must be repeated after emptying the bladder. Accuracy rate of the cystography is 85%–100% at bladder rupture.<sup>3</sup> Best et al<sup>4</sup> suggested open surgery as the most optimal method for the treatment of urethral injuries. In a retrospective analysis, however, Jackson et al<sup>5</sup> suggested that none of the urethral injuries require urethral substitution with graft and flaps as the first treatment. Contamination and inadequate circulation result with treatment failures.<sup>5</sup> Regarding bladder injuries, the bladder must be closed with 2 layers of absorbable sutures. The most important issue after the repair of bladder rupture is adequate drainage of the bladder. Thus, usage of a large-scaled urethral Foley catheter in addition to suprapubic cystostomy is recommended. The patient was operated by our department due to rectal bleeding



**Figure 2.** Computerized tomography scans showing perforation from the bladder neck.



**Figure 3.** Images from the operation room. (A) External view with rectal mucus in the wound. (B) External view with the light of the cystoscope. (C) The cystoscope is inserted from the urethra and the light and the tip of the cystoscope can easily be seen inside the wound.

and urethral and bladder injury. The urethra and the bladder were primarily repaired, a cystostomy was placed, and a long-term Foley drainage of the bladder was planned. The remnants of the prostate were debrided and also repaired before the reconstruction of the urethra, which is not reported previously.

### Conclusions

Multisystem traumas of the urethra, bladder, and rectum are seldom reported. Several forms of self-mutilation are known in schizophrenic patients; however, firing an explosive inside the body is an extreme condition. Explosive traumas should be managed carefully as the effects of thermal injury might be more severe than they seem. Even in those cases, reconstruction of the

posterior urethra and bladder neck might be a reasonable option with appropriate surgical techniques.

### References

1. Smith's General Urology, 16th ed; Chapter 17. Injuries to the genitourinary tract; 386.
2. Campbell-Walsh Urology, 10th ed. 2012;2507.
3. Brewer ME, Wilmoth RJ, Enderson BL, Daley BJ. Prospective comparison of microscopic and gross hematuria as predictors of bladder injury in blunt trauma. *Urology*. 2007;69:1086.
4. Best CD, Petrone P, Buscarini M, et al. Traumatic ureteral injuries: a single institution experience validating the American Association for the Surgery of Trauma-Organ Injury Scale grading scale. *J Urol*. 2005;173:1202.
5. Jackson DH, Williams JL. Urethral injury: a retrospective study. *Br J Urol*. 1974;46:665–676.