



# Comparison of magnesium versus titanium screw fixation for biplane chevron medial malleolar osteotomy in the treatment of osteochondral lesions of the talus

Baver Acar<sup>1</sup> · Ozkan Kose<sup>1</sup> · Melih Unal<sup>1</sup> · Adil Turan<sup>1</sup> · Yusuf Alper Kati<sup>1</sup> · Ferhat Guler<sup>1</sup>

Received: 19 April 2019 / Accepted: 30 July 2019 / Published online: 2 August 2019  
© Springer-Verlag France SAS, part of Springer Nature 2019

## Abstract

**Purpose** This retrospective study aimed to compare the clinical and radiological outcomes of patients who underwent biplane chevron medial malleolar osteotomy (MMO) for osteochondral lesions of the talus (OLT), fixed with either magnesium (Mg) or titanium (Ti) screws.

**Methods** A total of 22 patients (12 male and 10 female) with a mean age of  $40.6 \pm 12.5$  years (range 18–56 years) who underwent MMO for OLT treatment were included in this retrospective study. Of the 22 patients, MMO was fixed with bioabsorbable Mg screws (Alloy: MgYREZr) in 11 patients, and in the remaining 11 patients (one bilateral) MMO was fixed with Ti screws. All patients were followed up for at least 1 year with a mean of  $20.7 \pm 8.9$  months (range 12–49 months). The American Orthopedic Foot and Ankle Society (AOFAS) scale and the visual analog scale (VAS) were used to evaluate the clinical results. Union of the osteotomy, postoperative displacement and all other complications were followed and analyzed.

**Results** An improvement in the AOFAS scale and VAS points were recorded in both groups with no statistically significant difference between the groups ( $p$  0.079 and 0.107, respectively). Complete union of the osteotomy was obtained in all patients. One patient in the Ti group required implant removal due to pain and irritation. There were no other significant complications in either group.

**Conclusions** The results of this study showed that bioabsorbable Mg compression screws have similar therapeutic efficacy to Ti screws in respect of functional and radiological outcomes in MMO fixation. Bioabsorbable Mg screw is an alternative fixation material which can be safely used for MMO in ankle surgery.

**Level of evidence** Level IV, retrospective case series.

**Keywords** Osteochondral lesions of the talus · Magnesium screw · Bioabsorbable · Medial malleolar osteotomy

✉ Ozkan Kose  
drozkankose@hotmail.com

Baver Acar  
baveracar@hotmail.com

Melih Unal  
meliuh.unal@gmail.com

Adil Turan  
adilturan@yahoo.com

Yusuf Alper Kati  
alperkati@gmail.com

Ferhat Guler  
drferhatguler@gmail.com

<sup>1</sup> Department of Orthopedics and Traumatology, Antalya Training and Research Hospital, University of Health Sciences, Soğuksu mah. Kazım Karabekir cd., Muratpaşa, 07100 Antalya, Turkey

## Introduction

The majority of small- or medium-sized symptomatic osteochondral lesions of the talus (OLT) can be successfully treated with marrow-stimulation techniques through ankle arthroscopy which is a minimally invasive approach [1]. However, in large OLT lesions, particularly lesions exceeding  $15 \text{ mm}^2$ , the outcomes of arthroscopic treatment worsen over time with unacceptable failure rates [2]. Therefore, it is widely accepted that patients with large OLT should be treated with cartilage restorative procedures such as osteochondral autologous transplantation (OAT), autologous chondrocyte implantation (ACI), osteochondral allograft transplantation or autologous matrix-induced chondrogenesis (AMIC). However, these procedures usually necessitate an open ankle arthrotomy [3]. An anteromedial arthrotomy

may provide access to medial lesions located on the anterior portion of the talar dome, but most medial lesions are found in the middle or posterior aspects of the talus and are obscured by the medial malleolus [4, 5]. Thus, adequate exposure of most medial lesions through arthrotomy requires a medial malleolar osteotomy (MMO) mainly when restorative cartilage repair techniques are chosen for the treatment.

Ray and Coughlin first described a transverse MMO in 1947 for the treatment of OLT [6]. After that, several different configurations of MMO have been described such as oblique osteotomy, step-cut osteotomy, modified step-cut osteotomy, crescentic osteotomy, inverted U-osteotomy and inverted V-osteotomy [7–14]. Regardless of osteotomy type and technique, initial anatomic reduction and fixation of the osteotomy and maintenance of the reduction until complete bony union should be achieved after an MMO. In fact, the osteotomy itself is a source of secondary morbidity and is prone to several complications such as non-union, delayed union, malunion and irritation of fixation materials and the need for a subsequent removal operation [3]. Various fixation techniques and implants have been utilized to date, and the currently most commonly used implants are two parallel screws and/or buttress plates, alone or in combination [15].

As the soft tissue support is weak and subcutaneous fat is thin around the medial malleolar region, skin irritation, difficulty in shoe wearing and persistent pain overlying the distal tibial plates or screws are frequent even late after the union of osteotomy or fracture. In the current literature, the incidence of implant removal after MMO has been reported up to 71% [15–17]. This secondary surgical intervention both increases the cumulative cost of treatment and decreases patient satisfaction.

The use of bioabsorbable implants is a well-known application to eliminate the need for implant removal in orthopedic surgery. Previously, several bioabsorbable implants manufactured from various materials (particularly polyglycolic acid, polylactic acid and their copolymers) have been successfully used in both traumatic and elective foot and ankle surgery, although certain complications and adverse tissue reactions have been encountered [18]. Magnesium-based implants are relatively new generation among these bioabsorbable implants [19]. A limited number of clinical studies have been published about bioabsorbable magnesium screws in foot and ankle surgery up to date [20–26]. These previous studies suggest that magnesium implants with complete degradation properties are adequate for fracture or osteotomy fixation and eliminate the need for implant removal operations. Therefore, this implant may provide an advantage in the fixation of MMO that could require subsequent implant removal. In the current literature, no previous study investigates the efficacy or complications of bioabsorbable magnesium screws in MMO fixation. The purpose of this retrospective study was to compare the safety and

efficacy of bioabsorbable magnesium compression screws with standard titanium screws in MMO fixation.

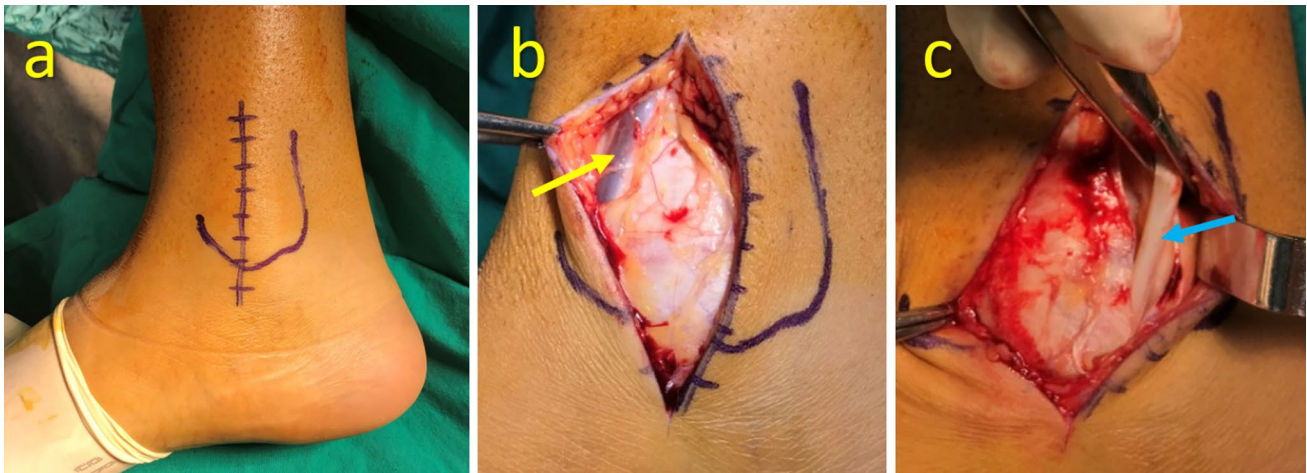
## Materials and methods

### Patients

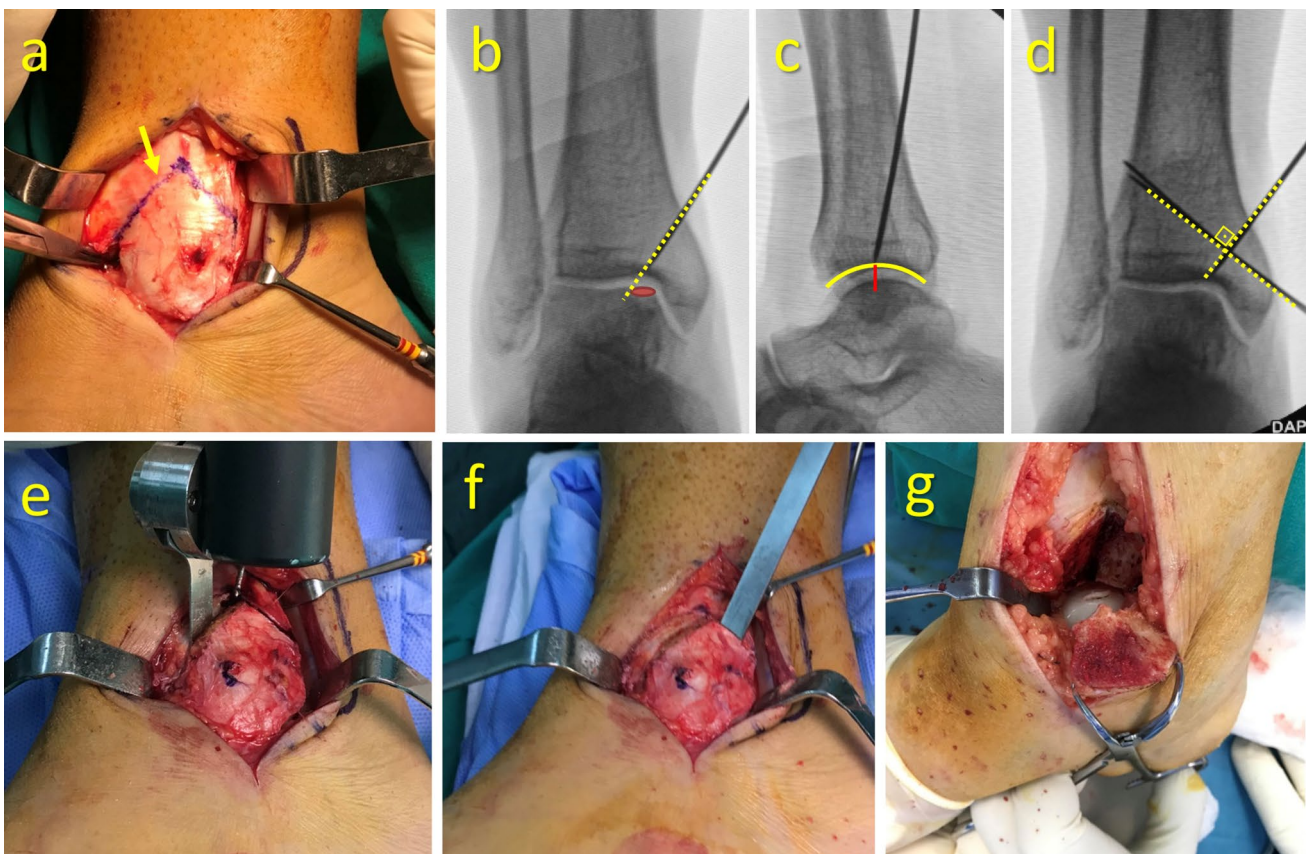
A retrospective review was performed on 22 patients with OLT who underwent a cartilage restorative procedure using the MMO approach between February 2015 and February 2018 in our hospital. Osteotomy fixation was achieved with two parallel headless compression screws made of either titanium or magnesium. The surgeon himself decided on the fixation technique and implants during the surgery, and no randomization was performed. The same surgeon performed all operations. Patients who were followed up for less than 12 months and patients whose osteotomy fixation was augmented with buttress plates were excluded from the study. None of the patients had previous surgical treatment. All radiological data which were stored in the picture archiving and communication system (PACS), patient charts, medical records, operation notes and notes taken during the follow-up visits were obtained from the institutional patient database and used to extract the demographic information, clinical findings and imaging findings. The Institutional Review Board approved the study protocol, and this study was carried out in accordance with the ethical standards laid down in the 1964 Declaration of Helsinki and its later amendments (as revised in Brazil in 2013). Informed consent was taken from all participants.

### Surgical technique and implants

Under spinal anesthesia in the supine position with a thigh tourniquet, a medial longitudinal (6–8 cm in length) incision was made over the medial malleolus (Fig. 1a). During superficial surgical dissection, the long saphenous vein and the accompanying saphenous nerve were protected at the anterior border of the medial malleolus (Fig. 1b). The flexor retinaculum was divided to identify the posterior tibial tendon and retracted posteriorly to expose the posterior surface of the malleolus (Fig. 1c). The anteromedial edge of the capsule was incised to see the plafond. A V-shaped chevron osteotomy limb was drawn on the bone with a surgical marker (Fig. 2a). A K-wire was inserted from the apex of the chevron osteotomy toward the desired location on the plafond according to the size of the lesion on the talus (Fig. 2b). The K-wire was positioned lateral to the lateral edge of the lesion on the AP fluoroscopic view and at the midline of the plafond on the lateral fluoroscopic view to facilitate the unrestricted vision of the lesion (Fig. 2c). After confirmation of the desired optimal position of the K-wire



**Fig. 1** **a** Medial longitudinal incision over the medial malleolus. **b** Long saphenous vein and the accompanying saphenous nerve (yellow arrow). **c** Posterior tibial tendon (blue arrow) (color figure online)



**Fig. 2** **a** V-shaped chevron osteotomy marked on the bone (yellow arrow). **b** On anteroposterior fluoroscopy view, the guidewire should be directed to the lateral edge of the lesion. **c** On lateral fluoroscopy view, the tip of the guidewire should be positioned at the midpoint of the distal tibial articular surface. **d** Two parallel guidewires which

will serve for final fixation are inserted perpendicular to the osteotomy plane. **e** The osteotomy is performed with a small oscillating blade down to the subchondral bone. **f** The osteotomy is finalized with an osteotome. **g** Medial malleolus is distracted and rotated, and the ankle is everted to expose the lesion (color figure online)

guide, two further parallel K-wires were inserted perpendicular to the previous K-wire for pre-drilling of the screw holes (Fig. 2d). These holes served as final fixation of the osteotomy in the anatomic position. The osteotomy was performed with an oscillating blade (Fig. 2e). The plane of the blade was kept parallel to the K-wire in each limb of the osteotomy plane to obtain a cone-shaped distal fragment. The oscillating blade was advanced down to the subchondral bone but not completely into the joint to protect the cartilage tissue. The osteotomy was finalized with a thin osteotome (Fig. 2f). The osteotomized fragment was rotated medially and distracted inferiorly with a towel clamp to visualize the lesion and provide enough space for the procedure (Fig. 2g). After completion of the cartilage restorative procedure, the osteotomy was reduced and fixed with two parallel compression screws using the pre-drilled holes while the reduction was kept safe with towel clamps. After sufficient compression was achieved and the screws were countersunk to the bone surface, a final fluoroscopic control view was taken to ensure the anatomic reduction of the osteotomy.


In three patients, autogenous osteochondral transplantation (Mosaicplasty™, Smith & Nephew, USA) was performed, and the osteochondral plugs were harvested from the periphery of the superolateral trochlea of the ipsilateral knee through a small arthrotomy incision. In the remaining 18 patients, the augmented marrow-stimulation technique using cell-free cartilage implant (The Alpha Chondro Shield®, Germany) was performed. Alpha Chondro Shield® is an absorbable non-woven textile fleece, which consists of pure polyglycolic acid (PGA) polymer. This cell-free cartilage implant aids the migration and differentiation of mesenchymal progenitor cells from the subchondral bone after a microfracture procedure (Fig. 3).

Bioabsorbable Mg screws (MAGNEZIX® CS, Syntellix AG, Hanover, Germany), which are made of magnesium

alloy (MgYREZr, Magnesium, Yttrium, Rare Earth Element, Zirconium), were used for the fixation of the osteotomy in ten patients. This screw is a variable pitch cannulated headless screw (3.2 mm Ø), which provides inter-fragmentary compression, similar to a Herbert screw. In the remaining 11 patients (1 bilateral) Titanium (Alloy: Ti 6Al 4V), headless compression screws (Acutrak®, Acumed, Hillsboro, USA) were used for the fixation. These were variable pitch cannulated headless compression screws (3.5 mm Ø), but the pitch varied continuously along the length (Fig. 4).

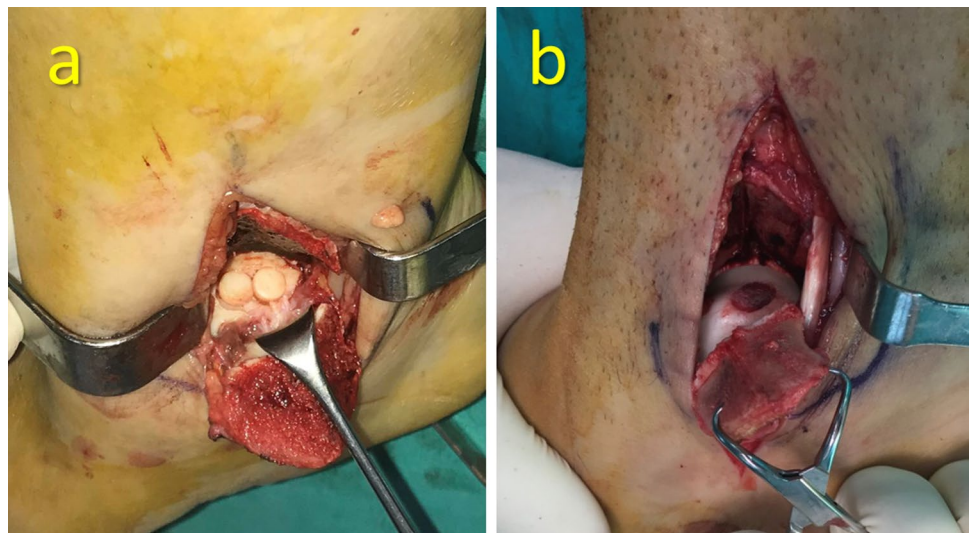
### Postoperative rehabilitation

All patients were immobilized in a short-leg splint in the neutral position for 6 weeks. After that, the splint was removed, and the active ankle range of motion (ROM) exercises were initiated. Total weight-bearing was encouraged at the end of 8–10 weeks following the radiographic findings



**Fig. 4** The appearance of **a** titanium and **b** magnesium headless compression screws used for the fixation of MMO

**Fig. 3** **a** Autologous osteochondral transplantation (AOT), mosaicplasty. **b** Autologous matrix-induced chondrogenesis (AMIC) treatment



of the union. Patients were followed up with monthly radiographic controls until the complete union was achieved. After the complete union, all daily activities were allowed without any restriction.

### Clinical and radiological evaluations

Functional outcomes were assessed with the American Orthopedic Foot and Ankle Society (AOFAS) score, and the pain was assessed using the visual analog scale (VAS) before the surgery and at the final follow-up examination. Any complications including infection, revision, ankle instability, tendon subluxation or synovitis and wound problems during the follow-up were recorded.

On initial admission, patients underwent standard anterior–posterior and lateral ankle radiographs and ankle magnetic resonance imaging (MRI). OLT was classified using the Hepple classification system on MRI [27]. The size of the lesion was measured on axial, coronal and sagittal MRI sections. The follow-up radiographs were used to evaluate the union of osteotomy and loss of reduction, or any displacement over time. Both clinical and radiological evaluations were blinded to the treating surgeon.

### Statistical analysis

A descriptive analysis of the continuous and categorical data was performed using proportions, frequency distributions, means and standard deviations. Comparison of independent variables was performed using the Student's *t* test or the Mann–Whitney *U* test in accordance with the conformity to normal distribution assessment. Differences within the same group were analyzed using the Paired sample *t* test, Wilcoxon test and Kruskal–Wallis test. Categorical variables were compared using the Chi-square test. A value of  $p < 0.05$  was accepted as statistically significant.

### Results

A total of 22 patients (12 male and 10 female) with a mean age of  $40.6 \pm 12.5$  years (range 18–56 years) were included in this retrospective study. Of the 22 patients, MMO was fixed with bioabsorbable Mg screws in 11 patients, and in the remaining 11 patients (1 bilateral) MMO was fixed with titanium screws (Table 1). All patients were followed up for at least 1 year with a mean of  $20.7 \pm 8.9$  months (range 12–49 months). Both groups were comparable in respect of demographic and clinical characteristics including age, gender distribution, side involvement, stage and size of the lesion, follow-up duration and the type of cartilage restorative procedure (Table 2).

Clinically significant improvements were obtained in both groups in both the AOFAS and VAS scores. At the final follow-up examination, there was no significant difference between the groups with respect to functional status (Table 3). The osteotomy union was achieved within the first 3 months, and there was no loss of reduction during the follow-up in either group (Fig. 5). In the Ti group, one patient had complaints of pain and irritation of the skin by prominent screw heads. The patient's discomfort was relieved after the removal of the screw at 22 months postoperatively. The rate of implant removal was statistically similar in both groups ( $n:1, n:0, p=0.522$ ). One of the patients who were treated with mosaicplasty had knee pain at the donor site, but the pain disappeared after eight months of follow-up.

In all patients where the MMO was fixed with Mg screws, a variable amount of gas accumulation within the soft tissue around the surgical site was observed in the early postoperative period on ankle radiographs. But there was no clinical sign or symptom related to gas in the soft tissues. Similarly, a radiolucent zone was observed around the screw within the bone in all patients (Fig. 6). This radiolucency completely disappeared within 6–12 months of follow-up. These radiological phenomena did not induce any clinical signs or symptoms in any patient and did not interfere with the osteotomy union. The screws were almost unidentifiable on radiographs that were taken 2 years postoperatively (Fig. 7).

### Discussion

This study was designed to compare the safety and efficacy of conventional titanium versus magnesium screw for the fixation of biplane chevron MMO in large OLT. None of the patients in either group developed malunion, non-union or any other complications due to MMO. Based on these findings, it was concluded that fixation of biplane chevron MMO with both implants was equally effective in achieving union. Furthermore, similar clinical outcomes were obtained in both groups. However, one patient in the Ti group required implant removal due to pain and irritation of the metallic screws. From this point of view, Mg screws seem to be advantageous as there was no need for implant removal.

A medial malleolar osteotomy (MMO) may be necessary particularly when restorative cartilage repair techniques are chosen for the treatment of medially located OLT. Actually, this intentionally created osteotomy can be a source of new morbidity and may deteriorate the final outcome of the whole procedure. Gaulrapp et al. reported worse clinical results and findings of radiographic osteoarthritis in patients with osteotomy compared to arthrotomy without osteotomy within 5 years after the treatment of OLT [28]. It is well known that even 1 mm of bone displacement or step-off on the medial malleolus increases the contact pressure of

**Table 1** List of all patients and their demographic and clinical characteristics

Case #	Fixation	Age	Sex	Side	Stage	Size (mm <sup>2</sup> )	Treatment	Follow-up (months)	Preop AOFAS	Postop AOFAS	Preop VAS	Postop VAS
1	Ti	44	M	L	V	143.5	AMIC	14	28	82	8	4
2	Ti	56	M	R	III	176.4	AMIC	24	33	97	8	0
3	Ti	37	F	R	III	217.2	AMIC	24	31	100	10	0
				L	III	180.9	AMIC	12	31	100	8	0
4	Ti	51	F	R	III	146.0	AMIC	23	33	100	10	2
5	Ti	52	M	R	IV	185.1	AMIC	49	65	100	7	1
6	Ti	51	F	L	III	174.6	AMIC	20	39	88	10	3
7	Ti	39	F	L	V	162.4	AOT	18	29	90	10	0
8	Ti	46	M	R	V	292.5	AMIC	14	62	80	10	1
9	Ti	30	M	R	V	283.9	AMIC	12	33	90	9	1
10	Ti	56	F	R	III	170.2	AMIC	12	33	75	9	2
11	Ti	36	F	R	III	198.0	AMIC	15	43	89	7	2
12	Mg	22	F	R	III	170.2	AMIC	20	33	84	8	0
13	Mg	23	M	L	III	142.4	AMIC	26	38	70	8	4
14	Mg	18	F	R	III	184.4	AMIC	30	66	76	7	3
15	Mg	30	M	L	V	144.3	AOT	24	27	88	10	5
16	Mg	31	M	R	IV	168.7	AMIC	34	80	97	5	0
17	Mg	56	M	L	III	178.8	AMIC	25	35	59	9	5
18	Mg	52	M	L	V	176.5	AMIC	13	62	97	7	0
19	Mg	36	M	R	III	167.2	AMIC	27	73	87	8	3
20	Mg	53	F	L	IV	174.2	AOT	14	38	90	10	2
21	Mg	24	M	R	III	280.0	AMIC	15	44	75	7	3
22	Mg	51	F	R	III	143.0	AOT	12	35	90	10	2

Ti titanium, Mg magnesium, M male, F female, R right, L left, AMIC autologous matrix-induced chondrogenesis, AOT autologous osteochondral transplantation, AOFAS American Orthopaedic Foot and Ankle Society, VAS Visual Analog Scale)

**Table 2** Demographic and clinical characteristics of patients

Variable	Magnesium group (n:11)	Titanium group (n:11)	p value
Age (years ± SD)	36.0 ± 14.3	45.2 ± 8.7	0.083
Sex (M/F)	7/4	5/6	0.670
Side (R/L)	6/5	8/4	0.433
Stage of the OLT (n)			
Stage III	7	7	0.619
Stage IV	2	1	
Stage V	2	4	
Size of the TOL (mm <sup>2</sup> ± SD)	175.4 ± 37.7	194.2 ± 48.3	0.314
Treatment (n)			
AOT	3	1	0.261
AMIC	8	11	
Follow-up (months ± SD)	21.8 ± 7.4	19.7 ± 10.3	0.591

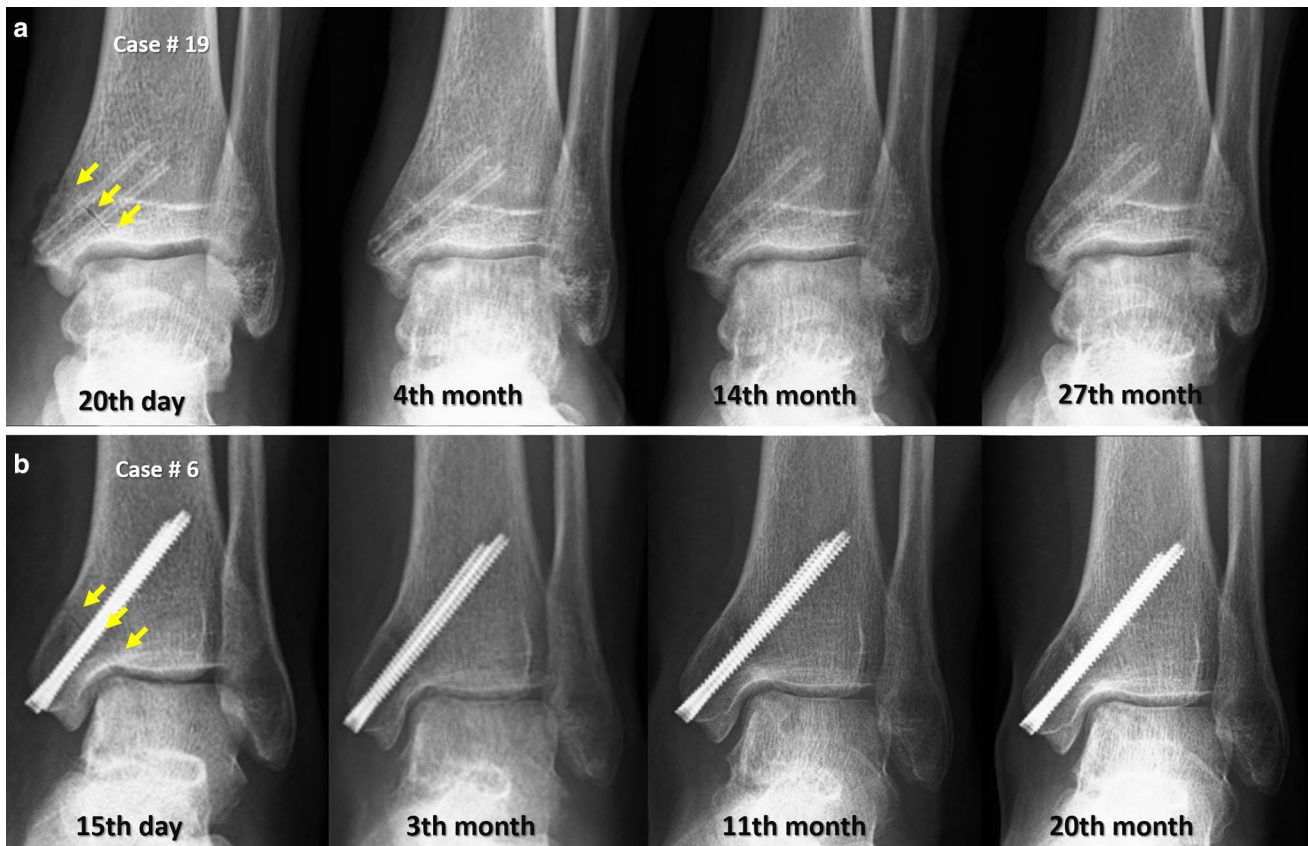M male, F female, R right, L left, AMIC autologous matrix-induced chondrogenesis, AOT autologous osteochondral transplantation

the ankle joint that may eventually lead to post-traumatic osteoarthritis [29]. Therefore, anatomic reduction and stable fixation of the MMO, and the union are critically important.

Although several studies are describing the exposure or focusing on the treatment of OLT, there are few reports on how to fix the MMO [14, 30, 31]. As MMO are prone

**Table 3** Comparison of functional outcomes between groups

Variable	Magnesium group (n:11)	Titanium group (n:12)	p value
Preop AOFAS (score $\pm$ SD)	48.2 $\pm$ 18.4	38.3 $\pm$ 12.4	0.141
Postop AOFAS (score $\pm$ SD)	83.0 $\pm$ 11.7	90.9 $\pm$ 8.7	0.079
p value	0.000	0.000	
Preop VAS (score $\pm$ SD)	8.0 $\pm$ 1.5	8.8 $\pm$ 1.1	0.215
Postop VAS (score $\pm$ SD)	2.4 $\pm$ 1.8	1.3 $\pm$ 1.3	0.107
p value	0.000	0.000	



**Fig. 5** **a** Magnesium screw fixation. Serial radiographic follow-up of Case #19 from the early postoperative period to the final follow-up in the 27th month. **b** Titanium screw fixation. Serial radiographic fol-

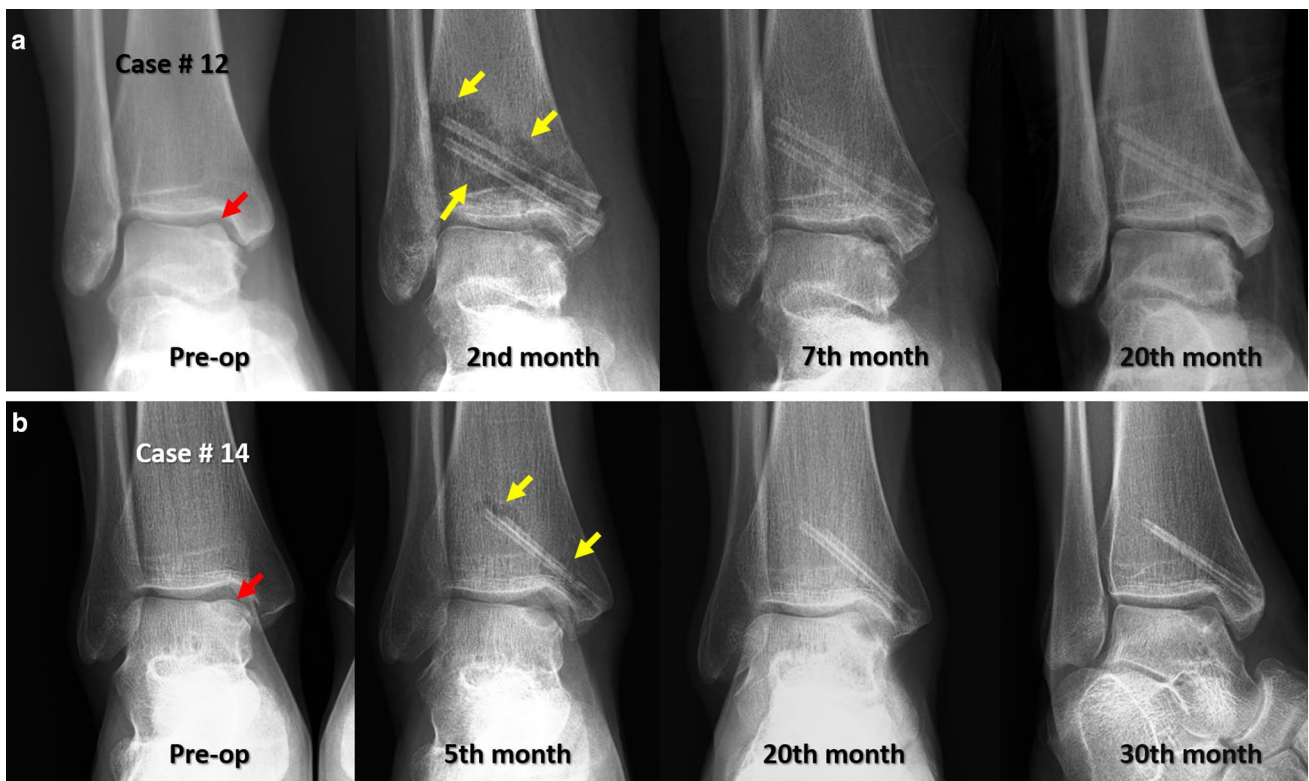
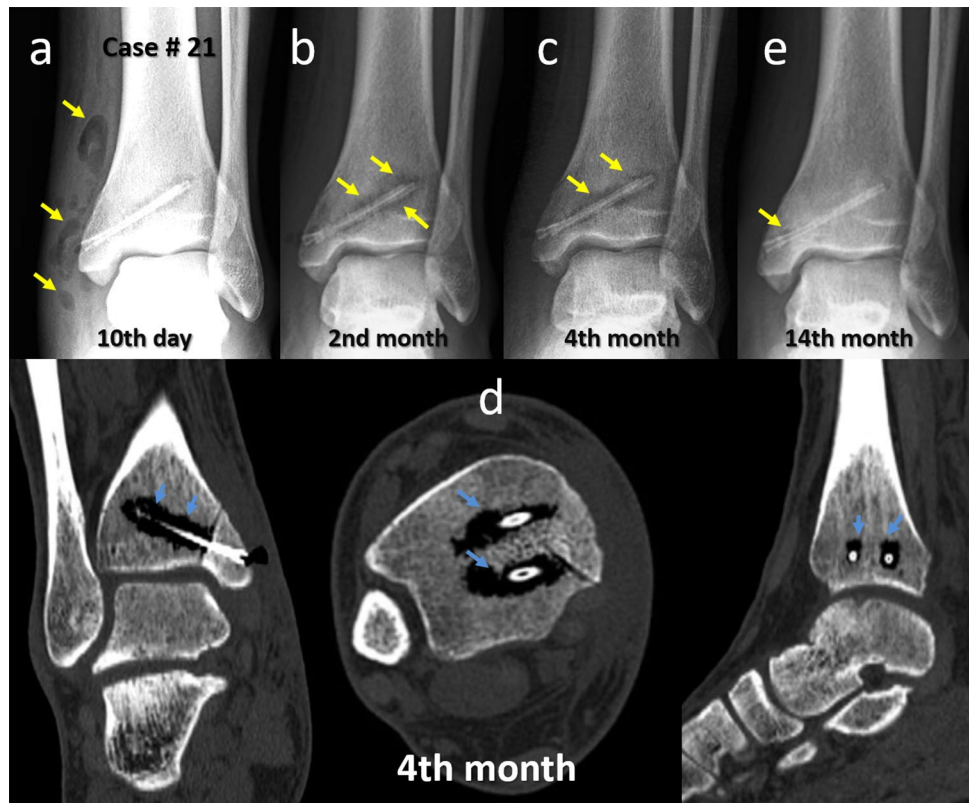
low-up of Case #6 from the early postoperative period to the final follow-up in the 27th month. Yellow arrows show the initial osteotomy plane (color figure online)

to technical errors, they should be cautiously approached. Although various fixation techniques and implants have been utilized to date, two parallel screws and/or buttress plates, alone or in combination, are among the most commonly used implants in current practice [15]. Bergen et al. reported that fixation of MMO with two parallel screws placed perpendicular to the direction of the osteotomy is sufficient for the maintenance of a congruent joint surface after anatomic reduction [30]. However, Lamb et al. proposed that an additional third screw placed in transverse orientation (parallel to the joint surface) would prevent the superior migration

of the osteotomy fragment. They reported no malunion case in their series of 62 MMO [31]. Cohen and Anderson noted minimal displacement (<2 mm) in 4 of 19 cases with two screws fixation [14]. Bull et al. reported a 30% malunion rate in patients who underwent biplane medial malleolar chevron osteotomy fixed with two lag screws. They stated that MMO fixation should be strengthened by buttress plates to eliminate postoperative osteotomy displacement [15].

Although only two screws were used in this study, no malunion or displacement developed in any patient. There may be several reasons to explain the findings in this study.

**Fig. 6** Serial radiographic follow-up of Case #21. **a** Early postoperative radiograph shows gas within the soft tissues (yellow arrows). **b** In the second month, a radiolucent zone around the screws within the bone is seen (yellow arrows). **c** In the fourth month, the radiolucency is decreased. **d** Coronal, axial and sagittal computerized tomography (CT) demonstrated the gas around the screws. **e** At the final follow-up in the 14th month, the radiolucent zone had almost completely disappeared, and the osteotomy was united without displacement. Please note the articular surface congruity throughout the serial radiographs (color figure online)



**Fig. 7** Two example cases showing gradual disappearance of the radiolucent zone around the magnesium implants on serial radiographic examinations. **a** Case# 12 and **b** Case# 14. In both cases, the union

was achieved in the anatomic position. The red arrow shows the talar lesion. Yellow arrows show the radiolucent zones around the screws at early postoperative radiographs (color figure online)

First, biplane chevron osteotomy creates a conical-shaped osteotomy fragment which has an inherent locking property (Fig. 8). This three-dimensional structure prevents superior migration in contrast to single-plane osteotomies such as oblique MMO [32]. Secondly, the biplane MMO creates a larger surface area which may be favorable for fracture healing. Another reason is that cartilage restoration procedures usually necessitate a relatively long immobilization period for cartilage healing. This time spent in a plaster cast without weight-bearing also provides a sufficient environment for fracture healing. For the reasons as mentioned above, it can be considered that two screws placed perpendicular to the osteotomy plane are adequate for fixation in the biplane chevron MMO.

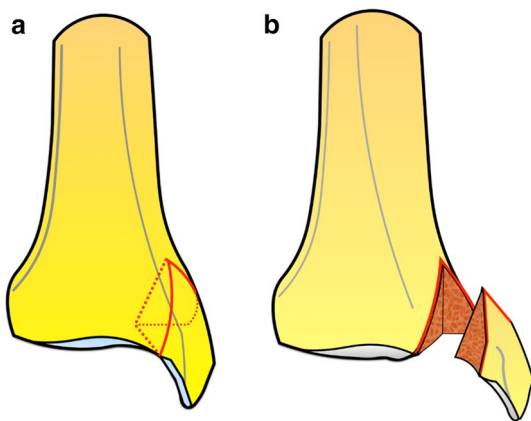
One of the most common problems in MMOs, apart from malunion and non-union, is the need to remove the metallic implants used for fixation with a second operation. A wide range of implant removal rates after MMO have been reported in the current literature. Peterson et al. reported that implants had to be removed in all of their patients (100%) [33]. Leumann et al. reported that 12 of 17 patients who underwent MMO osteotomy indicated that their implants had to be removed [17]. Bull et al. stated that the implant removal rate in their series was 71% [15]. Implant removal can result in significant complications such as soft tissue damage, fractures, infections and other problems. Furthermore, it has significant economic implications, including the costs of the procedure as well as possible work time lost for postoperative recovery [34, 35]. In the current study, no patient in the bioabsorbable Mg screw group needed implant removal. This stands out as the most important advantage of these screws. In the titanium screw group, only one screw removal was performed (8.3% removal rate). Unlike previous studies which used standard lag screws, it is likely that

the use in the current study of headless compression screws and countersinking the screw down to the bone surface lowered the rate of implant removal in the Ti group.

Mg screws are more expensive than conventional titanium or stainless-steel screws. However, when the cumulative cost of the treatment (including index operation, implant removal operation and indirect working day loss) is taken into consideration, use of bioabsorbable implants is cost-effective and advantageous, as they eliminate secondary removal operations and prevent loss of working days. Klauser carried out an economic analysis and compared magnesium with titanium screws in hallux valgus surgery in Germany. Approximately 9 million Euro would be saved if magnesium screws were used due to the lack of implant removal operations and consequent working day losts [26].

In this study, some radiological findings were observed in both soft tissue and the bone during the corrosion of the magnesium implants. It is well known that when Mg reacts with tissue fluids, free hydrogen gas is released in accordance with this chemical equation,  $Mg + 2 H_2O \rightarrow Mg(OH)_2 + H_2$  [36]. These degradation products, particularly  $Mg(OH)_2$ , are gradually absorbed and metabolized by the surrounding tissues. However, hydrogen gas ( $H_2$ ) may be observed in soft tissues around the surgical site without causing any local reaction or wound healing problem during the early postoperative period. Again, it also appears surrounding the screws in the bone and is similarly absorbed over time without interfering in the fracture healing process. Although it seems to be an osteolytic process, the corrosion products of Mg have been shown to have osteoinductive properties [37]. No non-union was observed in any patient in the Mg group. All these radiological appearances have also been reported in other studies using Mg-based implants. Therefore, physicians who will perform surgery with these implants should be aware of these unusual radiological phenomena. Furthermore, degradation products of magnesium biomaterials do not interfere with cartilage healing and do not cause an adverse inflammatory reaction in experimental studies [38].

There are some limitations to this study. First of all, this was a retrospective study, and the number of patients was limited, but the use of MMO is steadily declining due to recent advances in both the techniques and instruments used in ankle arthroscopy. Secondly, although all patients underwent similar exposure regarding MMO, two different cartilage restorative procedures were used, which may have affected the functional scores. However, this paper focused on MMO fixation and union, rather than the functional results of specific treatment modalities in OLT. Finally, patients were followed up for a mean of 20 months. This follow-up duration is sufficient for the monitoring of osteotomy union but may not be adequate to predict late-onset outcomes and complications. In addition to these limitations,



**Fig. 8** Illustration showing the three-dimensional shape of the biplane chevron medial malleolar osteotomy. **a** The red lines indicate the borders of the osteotomy on an intact tibia. **b** The osteotomized medial malleolus and its appearance (color figure online)

there were also some strong aspects of the study. All the operations were performed or supervised by the same orthopedic foot and ankle specialist. Thus, both the MMO and the fixation technique were similar in both groups. The same postoperative rehabilitation regime was applied to all patients, and both groups were comparable in respect of several baseline clinical characteristics. To the best of our knowledge, this is the first clinical study that has reported the outcome of magnesium bioabsorbable screw fixation in MMO.

In conclusion, fixation of biplane chevron MMO with either Mg or Ti screws resulted in similar rates of union and functional outcomes. None of the patients had displacement or malunion. The use of two perpendicular Mg screws provided satisfactory healing of the osteotomy with comparable results to conventional Ti screws. Due to the potential elimination of implant removal operations, the Mg screw seems to be an excellent candidate for the fixation of MMO in the future. The corrosion process of the Mg screws induces unusual radiographic findings during the follow-up, which most orthopedic surgeons may not be familiar with. This phenomenon neither causes any clinical symptom nor interferes with fracture union.

### Compliance with ethical standards

**Conflict of interest** All authors declare that they have no conflict of interest.

**Ethical approval** All procedures performed in studies involving human participants were in accordance with the ethical standards of the institutional and national research committee and with the 1964 Helsinki declaration and its later amendments or comparable ethical standards. IRB approved the study protocol.

**Informed consent** Informed consent was obtained from all individual participants included in the study.

### References

- van Bergen CJ, Kox LS, Maas M, Sierevelt IN, Kerkhoffs GM, van Dijk CN (2013) Arthroscopic treatment of osteochondral defects of the talus: outcomes at eight to twenty years of follow-up. *J Bone Jt Surg Am* 95(6):519–525
- Choi WJ, Park KK, Kim BS, Lee JW (2009) Osteochondral lesion of the talus: is there a critical defect size for poor outcome? *Am J Sports Med* 37(10):1974–1980
- Navid DO, Myerson MS (2002) Approach alternatives for treatment of osteochondral lesions of the talus. *Foot Ankle Clin* 7(3):635–649
- Young KW, Deland JT, Lee KT, Lee YK (2010) Medial approaches to osteochondral lesion of the talus without medial malleolar osteotomy. *Knee Surg Sports Traumatol Arthrosc* 18(5):634–637
- Elias I, Zoga AC, Morrison WB, Besser MP, Schweitzer ME, Raikin SM (2007) Osteochondral lesions of the talus: localization and morphologic data from 424 patients using a novel anatomical grid scheme. *Foot Ankle Int* 28(2):154–161
- Ray RB, Coughlin EJ Jr (1947) Osteochondritis dissecans of the talus. *J Bone Jt Surg Am* 29(3):697–706
- Spatt JF, Frank NG, Fox IM (1986) Transchondral fractures of the dome of the talus. *J Foot Surg* 25(1):68–72
- Mendicino RW, Lee MS, Grossman JP, Shromoff PJ (1998) Oblique medial malleolar osteotomy for the management of talar dome lesions. *J Foot Ankle Surg* 37(6):516–523
- Alexander IJ, Watson JT (1991) Step-cut osteotomy of the medial malleolus for exposure of the medial ankle joint space. *Foot Ankle Int* 11:242–243
- Lee KB, Yang HK, Moon ES, Song EK (2008) Modified step-cut medial malleolar osteotomy for osteochondral grafting of the talus. *Foot Ankle Int* 29(11):1107–1110
- Wallen EA, Fallat LM (1989) Crescentic transmalleolar osteotomy for optimal exposure of the medial talar dome. *J Foot Surg* 28(5):389–394
- Oznur A (2001) Medial malleolar window approach for osteochondral lesions of the talus. *Foot Ankle Int* 22:841–842
- O'Farrell TA, Costello BG (1982) Osteochondritis dissecans of the talus. The late results of surgical treatment. *J Bone Jt Surg Br* 64:494–497
- Cohen B, Anderson R (2002) Chevron-type transmalleolar osteotomy: an approach to medial talar dome lesions. *Tech Foot Ankle Surg* 1:158–162
- Bull PE, Berlet GC, Canini C, Hyer CF (2016) Rate of malunion following bi-plane Chevron medial malleolar osteotomy. *Foot Ankle Int* 37(6):620–626
- Gul M, Yavuz U, Cetinkaya E, Aykut US, Ozkul B, Kabukcuoglu YS (2015) Chevron osteotomy in patients with scheduled osteotomy of the medial malleolus. *Acta Orthop Traumatol Turc* 49(4):399–404
- Leumann A, Horisberger M, Buettner O, Mueller-Gerbl M, Valderrabano V (2016) Medial malleolar osteotomy for the treatment of talar osteochondral lesions: anatomical and morbidity considerations. *Knee Surg Sports Traumatol Arthrosc* 24(7):2133–2139
- Raikin SM, Ching AC (2005) Bioabsorbable fixation in foot and ankle. *Foot Ankle Clin* 10(4):667–684
- Seitz JM, Lucas A, Kirschner M (2016) Magnesium-based compression screws: a novelty in the clinical use of implants. *JOM* 68:1177–1182
- Plaass C, von Falck C, Ettinger S, Sonnow L, Calderone F, Weizbauer A, Reifernath J, Claassen L, Waizy H, Daniilidis K, Stukenborg-Colsman C, Windhagen H (2017) Bioabsorbable magnesium versus standard titanium compression screws for fixation of distal metatarsal osteotomies—3 year results of a randomized clinical trial. *J Orthop Sci* 2658(17):30300–30307
- Plaass C, Ettinger S, Sonnow L, Koenneker S, Noll Y, Weizbauer A, Reifernath J, Claassen L, Daniilidis K, Stukenborg-Colsman C, Windhagen H (2016) Early results using biodegradable magnesium screw for modified chevron osteotomies. *J Orthop Res* 34(12):2207–2214. <https://doi.org/10.1002/jor.23241>
- Windhagen H, Radtke K, Weizbauer A, Diekmann J, Noll Y, Kreimeyer U, Schavan R, Stukenborg-Colsman C, Waizy H (2013) Biodegradable magnesium-based screw clinically equivalent to titanium screw in hallux valgus surgery: short term results of the first prospective, randomized, controlled clinical pilot study. *Biomed Eng* 12:62. <https://doi.org/10.1186/1475-925X-12-62>
- Biber R, Pauser J, Brem M, Bail HJ (2017) Bioabsorbable metal screws in traumatology: a promising innovation. *Trauma Case Reports* 8:11–15
- Kose O, Turan A, Unal M, Acar B, Guler F (2018) Fixation of medial malleolar fractures with magnesium bioabsorbable headless compression screws: short-term clinical and

- radiological outcomes in eleven patients. *Arch Orthop Trauma Surg* 138(8):1069–1075
25. Acar B, Unal M, Turan A, Kose O (2018) Isolated lateral malleolar fracture treated with a bioabsorbable magnesium compression screw. *Cureus* 10(4):e2539
  26. Klauser H (2018) Internal fixation of three-dimensional distal metatarsal I osteotomies in the treatment of hallux valgus deformities using biodegradable magnesium screws in comparison to titanium screws. *Foot Ankle Surg*. <https://doi.org/10.1016/j.fas.2018.02.005>
  27. Hepple S, Winson IG, Glew D (1999) Osteochondral lesions of the talus: a revised classification. *Foot Ankle Int* 20(12):789–793
  28. Gaulrapp H, Hagena FW, Wasmer G (1996) Postoperative evaluation of osteochondrosis dissecans of the talus with special reference to medial malleolar osteotomy. *Z Orthop Ihre Grenzgeb* 134(4):346–353
  29. Lareau CR, Bariteau JT, Paller DJ, Koruprolu SC, DiGiovanni CW (2015) Contribution of the medial malleolus to tibiotalar joint contact characteristics. *Foot Ankle Spec* 8:23–28
  30. van Bergen CJ, Tuijthof GJ, Sierevelt IN, van Dijk CN (2011) Direction of the oblique medial malleolar osteotomy for exposure of the talus. *Arch Orthop Trauma Surg* 131(7):893–901
  31. Lamb J, Murawski CD, Deyer TW, Kennedy JG (2013) Chevron-type medial malleolar osteotomy: a functional, radiographic and quantitative T2-mapping MRI analysis. *Knee Surg Sports Traumatol Arthrosc* 21(6):1283–1288
  32. Granata JD, DeCarbo WT, Hyer CF, Granata AM, Berlet GC (2013) Exposure of the medial talar dome: bi-plane chevron medial malleolus osteotomy. *Foot Ankle Spec* 6(1):12–14
  33. Petersen W, Taheri P, Schliemann B, Achtnich A, Winter C, Forckel P (2014) Osteochondral transplantation for the treatment of osteochondral defects at the talus with the Diamond twin system (®) and graft harvesting from the posterior femoral condyles. *Arch Orthop Trauma Surg* 134(6):843–852
  34. Busam ML, Esther RJ, Obremeskey WT (2006) Hardware removal: indications and expectations. *J Am Acad Orthop Surg* 14(2):113–120
  35. Krettek C, Müller C, Meller R, Jagodzinski M, Hildebrand F, Gaulke R (2012) Is routine implant removal after trauma surgery sensible? *Unfallchirurg* 115(4):315–322. <https://doi.org/10.1007/s00113-012-2159-2>
  36. Waizy H, Seitz JM, Reifenrath Weizbauer A, Bach FW, Meyer-Lindenberg A, Denkena B, Windhagen H (2013) Biodegradable magnesium implants for orthopedic applications. *J Mater Sci* 48:39–5020
  37. Waizy H, Diekmann J, Weizbauer A, Reifenrath J, Bartsch I, Neubert V, Schavan R, Windhagen H (2014) In vivo study of a biodegradable orthopedic screw (MgYREZr-alloy) in a rabbit model for up to 12 months. *J Biomater Appl* 28:667–675
  38. Witte F, Ulrich H, Rudert M, Willbold E (2007) Biodegradable magnesium scaffolds: part 1: appropriate inflammatory response. *J Biomed Mater Res A*. 81(3):748–756

**Publisher's Note** Springer Nature remains neutral with regard to jurisdictional claims in published maps and institutional affiliations.