

A Case of Fetal Ovarian Cyst: Prenatal Detection, Postnatal Diagnostic Approach and Outcome

Derya Eroğlu¹, Gonca Tekant², Nilay Akhun³, Nilgün Kapucuoğlu²

¹Acıbadem University School of Medicine, Department of Obstetrics and Gynecology, Acıbadem Fulya Hospital, Istanbul, Turkey

²Acıbadem Maslak Hospital, Division of Pediatric Surgery, Istanbul, Turkey

³Acıbadem Fulya Hospital, Division of Radiology, Istanbul, Turkey

⁴Acıbadem Maslak Hospital, Division of Pathology, Istanbul, Turkey

Derya Eroğlu, Associate Prof.
Gonca Tekant, Prof.
Nilay Akhun, Specialist
Nilgün Kapucuoğlu, Prof.

Correspondence:

Associate Prof. Derya Eroğlu
Acıbadem University School of Medicine,
Department of Obstetrics and Gynecology,
Acıbadem Fulya Hospital, Istanbul, Turkey
Phone: +90 212 306 43 31-34
E-mail: d_eroğlu@hotmail.com

Received : 22 January 2016
Revised : 22 January 2016
Accepted : 07 March 2016

ABSTRACT

This paper describes the perinatal and postnatal outcome of a case considered to have a fetal ovarian cyst. At 29 weeks of gestation, routine ultrasound examination showed an anechoic cyst 15x16mm in diameter located in the abdomen at the left superolateral side of the bladder. The normal fetal anatomy of other abdominal organs and gender suggested an ovarian cyst as the most likely diagnosis and mesenteric or duplication cyst as differential diagnosis. Ultrasonographic follow-ups documented an increase in size to 40x22mm by 36 weeks of gestation. At postnatal 4 months, ultrasonographic scan showed a left-sided complex ovarian cyst 40x39mm in diameter containing fluid-debris levels and suggesting haemorrhage and/or torsion. At 4.5 months of age laparoscopic exploration demonstrated a normal right ovary and fallopian tube and a left ovary that had undergone torsion and remained a cystic structure. A laparoscopic left salpingo-oophorectomy was performed. Pathological examination demonstrated a microscopic amount of intact ovarian tissue. Fibrosis, dystrophic calcification and multinucleated cells were observed in the cyst wall, suggesting intrauterine torsion of the ovary. Torsion is one of the most serious complications that occur more frequently during fetal life than postnatally and may lead to loss of the gonad.

Key words: Neonatal ovarian cyst, ovarian cysts, ovariectomy, pregnancy

FETAL OVER KIST OLGUSU: PRENATAL TANI, POSTNATAL TANISAL YAKLAŞIM VE SONUÇ

ÖZET

Bu yazı, fetal over kisti olarak kabul edilen bir olgunun perinatal ve postnatal sonucunu tanımlamaktadır. 29. gebelik haftasında, rutin ultrasonografik incelemede abdomende mesanenin sol superolateral tarafında çapı 15x16 mm olan anekoik kist görüldü. Diğer fetal abdominal organların normal anatomisi ve cinsiyet en olasılıklı tanı olarak ovaryen kisti, ayırıcı tanıda ise mezenterik veya duplikasyon kistini düşündürdü. Ultrasonografik takipler kist çapındaki büyümenin 36. gebelik haftasına kadar 40x22 mm olduğunu gösterdi. Doğum sonrası 4. ayda, ultrasonografik incelemede, çapı 40x39 mm olan sol taraf yerleşimli, sıvı-debris içeren kompleks over kisti görüldü ve bu bulgular hemoraji ve/veya torsiyonu düşündürdü. Bebeğe 4.5 aylıkken yapılan laparoskopik incelemede, normal sağ over ve fallop tübü ve torsiyone olmuş kistik yapıdaki sol over görülerek sol salpingo-ooforektomi yapıldı. Patoloji raporunda mikroskopik düzeyde sağlam over dokusunun olduğu belirtildi. Kist duvarındaki fibrozis, distrofik kalsifikasyon ve çok çekirdekli hücreler over torsiyonunun intrauterin olduğunu düşündürdü. Torsiyon fetal hayatta postnatal döneme göre daha sıklıkla olan en önemli komplikasyonlardan birisidir ve gonadın kaybına neden olabilir.

Anahtar sözcükler: Neonatal over kisti, over kistleri, ooforektomi, gebelik

In female newborns ovarian cysts are one of the most frequent types of abdominal masses (1). The incidence of ovarian cysts in neonates has been estimated to be as frequent as 30%, based on autopsy studies (2,3). Stimulation of the fetal ovary by both placental and maternal hormones is generally considered to be responsible for the disease and explains why the majority of these cysts are benign follicular or functional theca-lutein (3). They are generally diagnosed at the end of the second and third trimesters of pregnancy (4).

Ovarian cyst detection on antenatal sonography has been well described in the literature. The diagnosis should be considered in a female fetus with a cystic structure in the pelvis or lower abdomen and normal urinary and gastrointestinal tracts (5,6). The differential diagnosis of fetal ovarian cysts can include an intestinal duplication cyst, lymphangioma, renal cystic dysplasia, urachal, mesenteric, omental and choledochal cysts, hydrometrocolpos and other intraabdominal tumors (7).

In this report, we describe the perinatal and postnatal outcome of a case considered to have a fetal ovarian cyst.

Case report

A 30 year-old primigravid woman applied for antenatal care in the first trimester. First trimester ultrasonographic evaluation revealed normal nuchal translucency thickness and fetal anatomy. At 29 weeks of gestation, routine ultrasound examination showed an anechoic cyst 15x16mm in diameter located in the abdomen at the left superolateral side of the bladder (Figure 1). The normal fetal anatomy of other abdominal organs and gender suggested an ovarian cyst as the most likely diagnosis and mesenteric or duplication cyst as differential diagnosis. The diameter of the cyst was measured as 37x24mm at 30+6 weeks of gestation (Figure 2). Twice-weekly ultrasound follow-ups documented the increase in size up to 40x22mm by 36 weeks of gestation. At 39 weeks of gestation, she gave birth to a female weighing 3460g with an Apgar score of 9 and 10 at 1 and 5 minutes, respectively. The infant had no problems post-delivery and physical examination was completely normal. At postnatal 4 months, ultrasonographic scan showed a left-sided complex ovarian cyst 40x39mm in diameter containing fluid-debris levels and suggesting haemorrhage and/or torsion (Figure 3). Pelvic MRI with intravenous contrast also confirmed the sonographic findings. At 4.5 months of age laparoscopic exploration demonstrated a normal right ovary and fallopian tube and a left ovary with a cystic structure that had

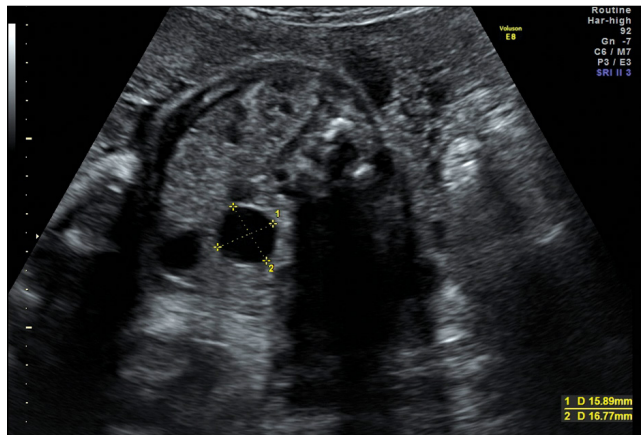


Figure 1. Prenatal ultrasonographic scan showing a fetal anechoic ovarian cystic mass measured 15x16 mm, with bladder shown inferiorly at 29 weeks of gestation.

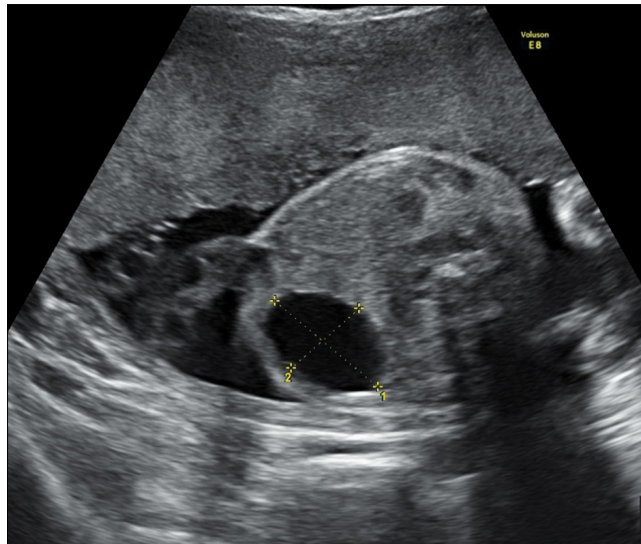


Figure 2. Prenatal ultrasonographic scan of the fetus documenting the increase in size to 37x24 mm at 30+6 weeks of gestation

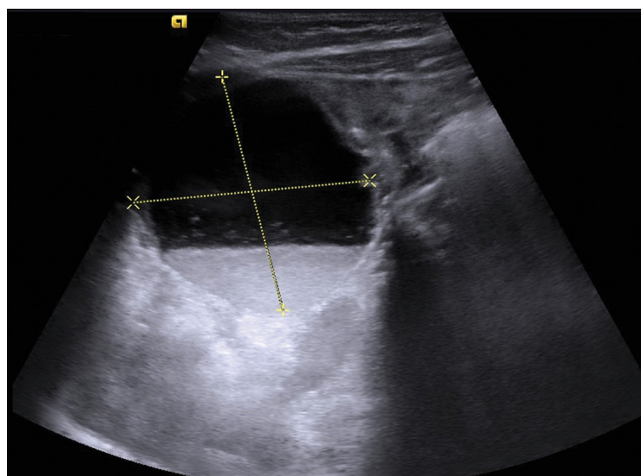


Figure 3. Postnatal ultrasonographic scan showed a complex ovarian cyst of 40x39 mm in diameter containing fluid-debris level and suggested haemorrhage and/or torsion

undergone torsion. A laparoscopic left salpingo-oophorectomy was performed. A microscopic amount of intact ovarian tissue was noted in the pathology report. Fibrosis, dystrophic calcification and multinucleated cells were observed in the cyst wall, suggesting intrauterine torsion of the ovary.

Discussion

Ovarian cysts are one of the most common etiologies of an intra-abdominal cyst (5,8). Small cysts have been identified in 34% of neonates (5). These are benign, functional cysts, apparently resulting from excessive stimulation by placental and maternal hormones (5,6). The sonographic appearances are variable depending on the size of the cyst and the presence of complications. The classic sonographic appearance of an uncomplicated ovarian cyst is that of an anechoic, unilocular mass in the fetal pelvis, usually in the third trimester. They can reach up to 10 cm in size (9). One third of ovarian cysts remain until the neonatal period (10). Spontaneous resolution of the ovarian and mesenteric cysts is not an infrequent finding. Additionally, mesenteric and ovarian cysts may have the same ultrasonographic appearance, which can also lead to misdiagnosis.

Cysts are rarely bilateral. Occasionally, internal septations are present. The presence of internal echoes, fluid levels or retracting clot suggests complications such as cyst torsion or hemorrhage (5,11). Complications may occur with the most common being ovarian torsion which may be seen during the course of up to 38-55% of pregnancies (12) and in 50-78% of cases during the neonatal period (13), with no difference between small and large cysts (14). Many of these torsions occur antenatally and, therefore, even the earliest surgical intervention after delivery may fail to preserve the ovary. Brandt et al (12) found that in 92% of cases explored for neonatal torsion, sonographic evidence of torsion was noted prenatally. Prenatal torsion can be detected in utero on the basis of changing appearances on serial sonograms from an anechoic cyst to a septated cyst, a cyst with a fluid-debris level or a cyst with solid components (12). In our case, antenatal sonographic

appearance of a thin-walled anechoic mass and the lack of internal echoes within the mass suggested that this was a simple cyst. Complex cystic appearance in the form of fluid-debris levels was observed in the postnatal period. Microscopic amount of intact ovarian tissue has been noted in the pathology report. Fibrosis, dystrophic calcification and multinucleated cells were observed in the cyst wall, suggesting intrauterine torsion of the ovary.

Polyhydramnios is associated with at least 10% of cases, possibly due to extrinsic compression of the small bowel (15).

The majority of ovarian cysts spontaneously regress postnatally in the absence of torsion (5). Some might even involute in utero (6). Very large cysts can lead to dystocia or respiratory distress as a result of diaphragmatic elevation (11).

Management depends on the size and presence of complications, with the majority being treated conservatively (15). Several authors suggest serial ultrasound examinations to follow all cysts until spontaneous resolution and prompt diagnosis of torsion (6,16). Other authors recommend serial ultrasound only for simple cysts smaller than 50 mm, with operative intervention for the remainder (11). Needle aspiration in utero has been advocated by some authors for large cysts (over 50 mm), to prevent torsion and obviate the need for neonatal laparotomy (17). If there is evidence of torsion late in pregnancy, early delivery and surgical cystectomy might be indicated to attempt to salvage the ovary (5,6,13). However, unless the diagnosis is made very soon after the event, intervention is likely to be fruitless. Other complications, such as intestinal volvulus and obstruction, might also warrant surgical resection (13).

Torsion of the ovary is one of the most serious complications that occur more frequently during fetal life than postnatally and may lead to loss of the cystic gonad. Thus, the management in the case of a suspected ovarian cyst should consist of serial ultrasound examination in order to search for possible complications (hydramnios, ascites, torsion).

References

1. Crombleholme TM, Craigo SD, Garmel S, Dalton ME. Fetal ovarian cyst decompression to prevent torsion. *J Pediatr Surg* 1997;32:1447-9.
2. Bryant AE, Laufer MR. Fetal ovarian cysts: incidence, diagnosis and management. *J Reprod Med* 2004;49:329-37.
3. deSA DJ. Follicular ovarian cysts in stillbirths and neonates. *Arch Dis Child* 1975;50:45-50.
4. Heling KS, Chaoui R, Kircmair F, et al. Fetal ovarian cysts: Prenatal diagnosis, management and postnatal outcome. *Ultrasound Obstet Gynecol* 2002;20:47-50.
5. Meizner I, Levy A, Katz M, Maresh AJ, Glezerman M. Fetal ovarian cysts: Prenatal ultrasonographic detection and postnatal evaluation and treatment. *Am J Obstet Gynecol* 1999;164:874-8.
6. Rizzo N, Gabrielle S, Perolo A et al. Prenatal diagnosis and management of fetal ovarian cysts. *Prenatal Diagn* 1989;9:97-104.
7. Brandt ML, Helmuth MA. Ovarian cysts in infants and children. *Semin Pediatr Surg* 2005;14:78-85.
8. Nyberg D, Mahoney B, Pretorius D, eds. *Diagnostic Ultrasound in Fetal Anomalies*. Year Book Medical, Chicago, 1990.
9. Twining P, McHugo J, Pilling D. *Textbook of Fetal Abnormalities*. Churchill Livingstone, Edinburgh, 2000.
10. Foley PT, Ford WD, McEwing r, Furness M: Is conservative management of prenatal and neonatal ovarian cysts justifiable? *Fetal Diagn Ther* 2005;20:454-8.
11. Suita S, Handa N, Nakano H. Antenatally detected ovarian cysts-a therapeutic dilemma. *Early Human Dev* 1992;29:363-7.
12. Brandt ML, Luks FI, Filiatrault D, Garel L, Desjardins JG, Youssef S. Surgical indications in antenatally diagnosed ovarian cysts. *J Pediatr Surg* 1991;26:276-82.
13. Bagolan P, Rivosecchi M, Giorlandino C, Bilancioni E, Nahom A, Zaccara A, Trucchi A, Ferro F. Prenatal diagnosis and clinical outcome of ovarian cysts. *J Pediatr Surg* 1992;27:879-81.
14. Sakala EP, Leon ZA, Rouse GA. Management of antenatally diagnosed fetal ovarian cysts. *Obstet Gynecol Surv* 1991;46:407-14.
15. Muller-Leisse C, Bick U, Paulussen K et al. Ovarian cysts in the fetus and neonate-changes in sonographic pattern in the follow up and their management. *Pediatr Radiol* 1992;22:395-400.
16. Zamora M, Gonzalez N. Spontaneous resolution of a sonographically complicated fetal ovarian cyst. *J Ultrasound Med* 1992;11:567-9.
17. Crombleholme T, Craigo S, Garmel S, D'Alton ME. Fetal cyst decompression to prevent torsion. *J Ped Surg* 1997;32:1447-9.