

## LETTER

# New onset of pemphigus foliaceus following BNT162b2 vaccine

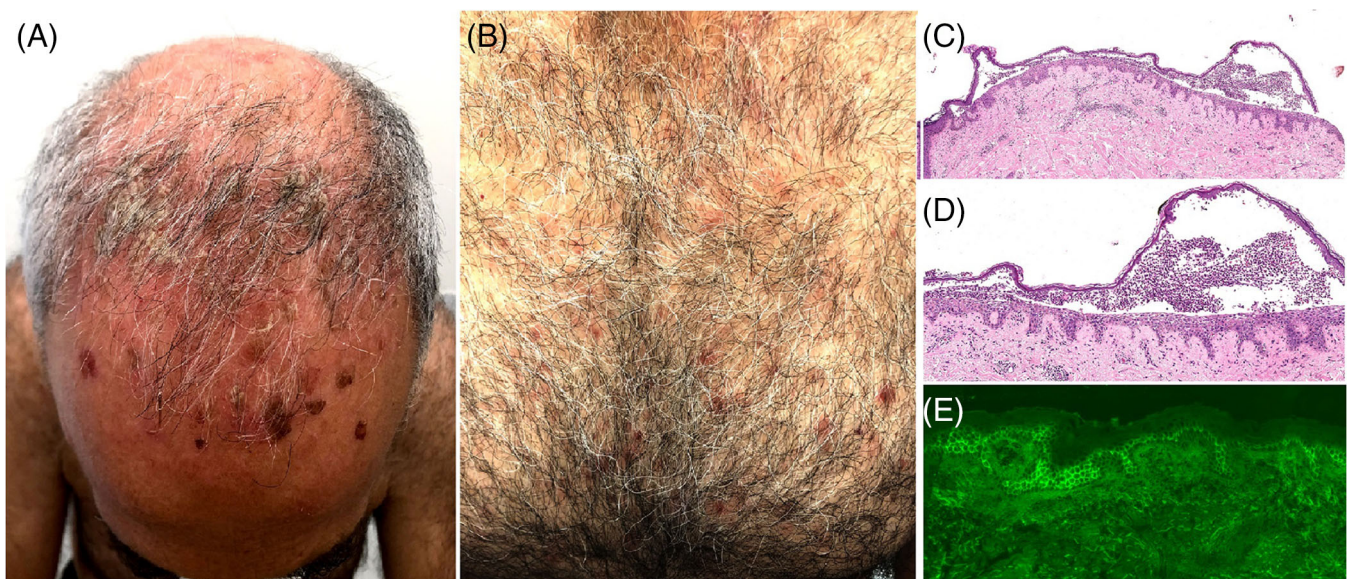
Dear Editor,

A 65-year-old man was referred to the dermatology clinic with blisters. The lesions started one week ago as multiple lesions with scaling on his chest, back and scalp (Figure 1). Oral mucosa was normal. One month ago, the patient had the BNT162b2 mRNA COVID-19 vaccine (Comirnaty, Biontech/Pfizer). He had hypertension for 10 years, and he has been using nebivolol 5 mg/day orally. A pill containing valsartan-hydrochlorothiazide combination was added to the treatment four months ago. Informed consent was obtained from the patient.

Lesional biopsy with hematoxylin-eosin stain showed intraepidermal acantholytic blister formation. Abundant neutrophils and scarce eosinophils were present in the lumen of the blister. Direct immunofluorescence (DIF) showed intercellular deposition of IgG and C3 within the epidermis (Figure 1). In the patient's serum, antibodies against desmoglein-1 (1/100 [EUROIMMUN]) were detected with quantitative enzyme immunoassay. Anti-desmoglein-3 antibodies were not present. The patient was diagnosed with pemphigus foliaceus (PF) and treated with 48 mg/day oral prednisolone and azathioprine 100 mg/day. The response to treatment was evident with two weeks of therapy. Currently, the only mRNA vaccine available in

Turkey is BNT162b2. Despite the possibility of exacerbation, the patient received the second dose of the BNT162b2 vaccine six weeks after the first vaccination. Two weeks after the second vaccine, multiple new lesions on the neck, back and gluteal region developed. Exacerbation subsided with topical treatments and the continuation of the therapy.

Viral infections and vaccinations can provoke autoimmune disease processes. SARS-CoV-2 is associated with autoimmune diseases such as Kawasaki disease, Guillain Barre Syndrome, and Miller Fisher Syndrome.<sup>1</sup> There are few COVID-19 triggered pemphigus vulgaris (PV) cases in the literature.<sup>2,3</sup> Molecular mimicry and bystander activation are proposed as the possible underlying mechanisms for the autoimmunity related to the SARS-CoV-2 virus.<sup>1</sup> Cross-reactivity between SARS-CoV-2 spike protein antibody and human tissue proteins such as TGase2, TGase3, collagen and S100B was recently proposed as potential sources of autoimmunity.<sup>4</sup> The bullous pemphigoid (BP) and PV was reported following SARS-CoV2 vaccinations.<sup>5</sup> In a case series, five patients with existing autoimmune blistering diseases (AIBD) (3 BP [2 Moderna 1 Pfizer] and 2 PV [1 Moderna, 1 Pfizer]) had flare-ups after vaccination.<sup>5</sup> All five patients were in remission at least for 6 months. One patient with BP vaccinated with Moderna COVID-19



**FIGURE 1** The erosions and scaling (A) on the scalp and (B) chest. (C, D) Intraepidermal acantholytic blister formation in the lesional skin (HE). Abundant neutrophils and scarce eosinophils in the lumen of the blister are seen (E) Direct immunofluorescence shows intercellular deposition of IgG and C3 within the epidermis in perilesional skin

had extensive oral mucosa involvement. The onset of lesions ranged between 3 days to 2 weeks after the vaccination. The transient bystander immune activation by the vaccine may have resulted in activation of previously existing subclinical inflammation in these cases.

Subepidermal bullous dermatitis after receiving the first or second dose of SARS-CoV-2 mRNA vaccines (8 Pfizer, 4 Moderna) was reported in 12 patients without a history of BP or autoimmunity. All patients had severe pruritus. Histopathological examination showed subepidermal or subcorneal blisters with eosinophils. DIF from perilesional skin revealed IgG/IgA and C3 positivity in the dermo-epidermal junction.<sup>6</sup> Currently, there are two reports of PV onset after the SARS-CoV2 vaccination. First is reported in a 40-year-old otherwise healthy female patient with painful erosions in oral mucosa 5 days following the mRNA vaccine BNT162b2, and worsening in her lesions after administration of 2nd dose.<sup>7</sup> Second is a 38-year-old female patient who had painful oral lesions that appeared 1 week after administering the first AZD1222 vaccine.<sup>8</sup>

We cannot rule out the coincidental onset of PF and vaccination in our patient. There is one case of valsartan and hydrochlorothiazide induced PF in the literature, and we cannot confidently disregard the possible effect.<sup>9</sup> However, the onset of the initial lesions after the first dose of vaccine and the exacerbation with new-onset generalized lesions after the second dose suggest the association with mRNA vaccine. In our case, disease course was controlled easily with the proper treatment regimen. Currently, the patient is under remission and is using azathioprine 100 mg/day. There is no consensus approach for further vaccination scheduling in such cases yet. If possible, switching to a different effective vaccine may be recommended. In our case, we recommended to continue with the mRNA vaccine BNT162b2 because of the emergence of new COVID-19 variants and the inefficiency of the alternative vaccine in our country.

#### CONFLICT OF INTEREST

The authors declare that they have no conflict of interest.

#### AUTHOR CONTRIBUTIONS

**Şebnem Yıldırıcı**: Wrote the draft of the paper; **Seçil Vural**: Primary physician of the patient, collected data, wrote, and revised the paper; **Savaş Yaylı**: Primary physician, revised the paper, contributed to revisions; **Cüyan Demirkessen**: Contributed to diagnosis by pathological examination.


#### DATA AVAILABILITY STATEMENT

The data that support the findings of this study are available on request from the corresponding author. The data are not publicly available due to privacy or ethical restrictions.

Şebnem Yıldırıcı<sup>1</sup> 

Savaş Yaylı<sup>1</sup>

Cüyan Demirkessen<sup>2</sup>

Seçil Vural<sup>1</sup> 

<sup>1</sup>Department of Dermatology and Venereology, Koç Üniversitesi Hastanesi, Topkapı, İstanbul, Turkey

<sup>2</sup>Department of Pathology, School of Medicine, Acıbadem Mehmet Ali Aydınlar University, İstanbul, Turkey

#### Correspondence

Seçil Vural, Department of Dermatology, Koç Üniversitesi Hastanesi, Topkapı, Davutpaşa Cd. No:4, Postal code: 34010, Zeytinburnu/İstanbul, Turkey.  
Email: [sevural@ku.edu.tr](mailto:sevural@ku.edu.tr)

#### Funding information

None.

#### ORCID

Şebnem Yıldırıcı  <https://orcid.org/0000-0002-3341-1709>

Seçil Vural  <https://orcid.org/0000-0001-6561-196X>

#### REFERENCES

- Ehrenfeld M, Tincani A, Andreoli L, et al. Covid-19 and autoimmunity. *Autoimmun Rev.* 2020;19:102597.
- Ghalamkarpour F, Pourani MR. Aggressive course of pemphigus vulgaris following COVID-19 infection. *Dermatol Ther.* 2020;33:e14398.
- De Medeiros VLS, Monteiro-Neto AU, Franca DDT, Castelo Branco R, de Miranda Coelho EO, Takano DM. Pemphigus vulgaris after COVID-19: a case of induced autoimmunity. *SN Compr Clin Med.* 2021;3:1-5.
- Vojdani A, Kharratian D. Potential antigenic cross-reactivity between SARS-CoV-2 and human tissue with a possible link to an increase in autoimmune diseases. *Clin Immunol.* 2020;217:108480.
- Damiani G, Pacifico A, Pelloni F, Iorizzo M. The first dose of COVID-19 vaccine may trigger pemphigus and bullous pemphigoid flares: is the second dose therefore contraindicated? *J Eur Acad Dermatol Venereol.* 2021;35:e645-e647.
- Tomayko MM, Damsky W, Fathy R, et al. Subepidermal blistering eruptions, including bullous pemphigoid, following COVID-19 vaccination. *J Allergy Clin Immunol.* 2021;148:750-751.
- Solimani F, Mansour Y, Didona D, Dilling A, Ghoreschi K, Meier K. Development of severe pemphigus vulgaris following SARS-CoV-2 vaccination with BNT162b2. *J Eur Acad Dermatol Venereol.* 2021;35:e649-e651.
- Thongprasom K, Pengpis N, Phattarataratip E, Samaranayake L. Oral pemphigus after COVID-19 vaccination. *Oral Dis.* 2022. <https://doi.org/10.1111/odi.14034>
- Giménez-García R, Nuñez-Cabezón M. Valsartan/hydrochlorothiazide induced pemphigus foliaceus. *Int J Allerg Medications.* 2016;2:012.