

The course of spinal tuberculosis (Pott disease): results of the multinational, multicentre Backbone-2 study

A. Batirel¹, H. Erdem², G. Sengoz³, F. Pehlivanoglu³, E. Ramosaco⁴, S. Gülsün⁵, R. Tekin⁶, B. Mete⁷, İ. İ. Balkan⁷, D. Y. Sevgi⁸, E. Giannitsioti⁹, A. Fragou⁹, S. Kaya¹⁰, B. Cetin¹¹, T. Oktenoglu¹², A. D. Celik¹³, B. Karaca¹⁴, E. S. Horasan¹⁵, M. Ulug¹⁶, S. Senbayrak¹⁷, S. Kaya⁵, E. Arslanalp¹⁸, R. Hasbun¹⁹, S. Ates-Guler²⁰, A. Willke¹⁸, S. Senol²¹, D. Inan²², E. Güclü²³, G. T. Ertem²⁴, M. M. Koc¹⁸, M. Tasbakan²⁵, G. Ocal¹, S. Kocagoz²⁶, H. Kusoglu²⁶, T. Güven²⁷, A. I. Baran²⁸, B. Dede²⁹, F. Y. Karadag³⁰, H. Yilmaz³¹, G. Aslan³², D. A. Al-Gallad³³, S. Cesur²⁴, R. El-Sokkary³⁴, F. Sirmatel³⁵, U. Savasci³⁶, G. Karaahmetoglu³⁷ and H. Vahaboglu³⁰

1) Dr Lutfi Kirdar Training and Research Hospital, Istanbul, 2) Gulhane Medical Academy, Department of Infectious Diseases and Clinical Microbiology, Ankara, 3) Haseki Training and Research Hospital, Department of Infectious Diseases and Clinical Microbiology, Istanbul, Turkey, 4) Infectious Diseases Hospital, University Hospital Center "Mother Teresa", Tirana, Albania, 5) Diyarbakir Training and Research Hospital, 6) Dicle University School of Medicine, Department of Infectious Diseases and Clinical Microbiology, Diyarbakir, 7) Istanbul University Cerrahpasa School of Medicine, 8) Sisli Etfal Training and Research Hospital, Department of Infectious Diseases and Clinical Microbiology, Istanbul, Turkey, 9) Department of Internal Medicine, Athens University Medical School, Attikon University General Hospital, Athens, Greece, 10) Karadeniz Technical University School of Medicine, Department of Infectious Diseases and Clinical Microbiology, Trabzon, 11) Koc University School of Medicine, Department of Infectious Diseases and Clinical Microbiology, 12) Koc University School of Medicine, Department of Neurosurgery, Istanbul, 13) Trakya University School of Medicine, Department of Infectious Diseases and Clinical Microbiology, Edirne, 14) Izmir Bozyaka Training and Research Hospital, Department of Infectious Diseases and Clinical Microbiology, Izmir, 15) Mersin University School of Medicine, Department of Infectious Diseases and Clinical Microbiology, Mersin, 16) Private Umit Hospital, Department of Infectious Diseases and Clinical Microbiology, Eskisehir, 17) Haydarpasa Numune Training and Research Hospital, Department of Infectious Diseases and Clinical Microbiology, Istanbul, 18) Kocaeli University School of Medicine, Department of Infectious Diseases and Clinical Microbiology, Kocaeli, 19) The University of Texas Health Science Center at Houston, Medical School, Department of Infectious Diseases, 20) Sutcu Imam University, School of Medicine, Department of Infectious Diseases and Clinical Microbiology, Kahramanmaraş, 21) Celal Bayar University, School of Medicine, Department of Infectious Diseases and Clinical Microbiology, Manisa, 22) Akdeniz University School of Medicine, Department of Infectious Diseases and Clinical Microbiology, Antalya, 23) Sakarya University School of Medicine, Department of Infectious Diseases and Clinical Microbiology, Sakarya, 24) Ankara Training and Research Hospital, Department of Infectious Diseases and Clinical Microbiology, Ankara, 25) Ege University School of Medicine, Department of Infectious Diseases and Clinical Microbiology, Izmir, 26) Acibadem University School of Medicine, Department of Infectious Diseases and Clinical Microbiology, Istanbul, 27) Ankara Atatürk Training and Research Hospital, Department of Infectious Diseases and Clinical Microbiology, Ankara, 28) Yuzuncuyil University School of Medicine, Department of Infectious Diseases and Clinical Microbiology, Van, 29) Umraniye Training and Research Hospital, Department of Infectious Diseases and Clinical Microbiology, 30) Medeniyet University, Goztepe Training and Research Hospital, Department of Infectious Diseases and Clinical Microbiology, Istanbul, 31) Ondokuz Mayıs University School of Medicine, Department of Infectious Diseases and Clinical Microbiology, Samsun, 32) Diskapi Yildirim Beyazit Training and Research Hospital, Department of Infectious Diseases and Clinical Microbiology, Ankara, Turkey, 33) Neurosurgery Department, 34) Medical Microbiology and Immunology, Infection Control Unit, Zagazig University, Zagazig, Egypt, 35) Izzet Baysal University School of Medicine, Department of Infectious Diseases and Clinical Microbiology, Bolu, 36) Gulhane Medical Academy, Department of Infectious Diseases and Clinical Microbiology, Ankara and 37) GATA Haydarpasa Training Hospital, Department of Infectious Diseases and Clinical Microbiology, Istanbul, Turkey

Abstract

We aimed to describe clinical, laboratory, diagnostic and therapeutic features of spinal tuberculosis (ST), also known as Pott disease. A total of 314 patients with ST from 35 centres in Turkey, Egypt, Albania and Greece were included. Median duration from initial symptoms to the time of diagnosis was 78 days. The most common complications presented before diagnosis were abscesses (69%), neurologic deficits (40%), spinal instability (21%) and spinal deformity (16%). Lumbar (56%), thoracic (49%) and thoracolumbar (13%) vertebrae were the most commonly involved sites of infection. Although 51% of the patients had multiple levels of vertebral involvement, 8% had noncontiguous involvement of multiple vertebral bodies. The causative agent was identified in 41% of cases. Histopathologic examination was performed in 200 patients (64%), and 74% were consistent with tuberculosis. Medical treatment alone was implemented in 103 patients (33%), while 211 patients (67%) underwent diagnostic and/or therapeutic surgical intervention. Ten percent of the patients required more than one

surgical intervention. Mortality occurred in 7 patients (2%), and 77 (25%) developed sequelae. The distribution of the posttreatment sequelae were as follows: 11% kyphosis, 6% Gibbus deformity, 5% scoliosis, 5% paraparesis, 5% paraplegia and 4% loss of sensation. Older age, presence of neurologic deficit and spinal deformity were predictors of unfavourable outcome. ST results in significant morbidity as a result of its insidious course and delayed diagnosis because of diagnostic and therapeutic challenges. ST should be considered in the differential diagnosis of patients with vertebral osteomyelitis, especially in tuberculosis-endemic regions. Early establishment of definitive aetiological diagnosis and appropriate treatment are of paramount importance to prevent development of sequelae.

Clinical Microbiology and Infection © 2015 European Society of Clinical Microbiology and Infectious Diseases. Published by Elsevier Ltd. All rights reserved.

Keywords: Pott disease, spinal tuberculosis, spondylitis, spondylodiscitis, vertebral osteomyelitis

Original Submission: 13 May 2015; **Revised Submission:** 20 July 2015; **Accepted:** 21 July 2015

Editor: W. Zimmerli

Article published online: 30 July 2015

Corresponding author: H. Erdem, GATA, Enfeksiyon Hastalıkları ve Klinik Mikrobiyoloji A.D., Etlik-Ankara, Turkey
E-mail: hakanerdem1969@yahoo.com

We sought to describe clinical, laboratory, diagnostic and therapeutic features, and clinical outcomes of ST in a large series of patients.

Introduction

Tuberculosis (TB) is a global health problem infecting one-third of the world's population. It is a widespread disease, with 8.7 million new cases annually, and worldwide rates of TB have increased in parallel with AIDS incidence [1]. In addition, TB ranks second, just after HIV infection, among infectious causes of mortality. Turkey has been reported to be a low-incidence country for TB [2,3]. When extrapulmonary TB is taken into consideration, 10–35% of the cases refer to spinal tuberculosis (ST), also known as Pott disease [4,5].

Spondylodiscitis (SD) or vertebral osteomyelitis (VOM) usually involves the inflammation or infection of the intervertebral disc and the adjacent vertebrae. This disease is most commonly seen in patients older than 50 years, with a male predominance; it leads to significant morbidity [6–9]. The aetiological agents of VOM may be bacteria, fungi or parasites, and their incidence varies in different geographical areas and with underlying diseases [7,10]. When the infecting agent is *Mycobacterium tuberculosis* complex, it is called ST [1]. In previous reports, delayed diagnosis and management are the major factors determining unfavourable outcomes such as spinal cord compression and deformities [7,11]. It may result in vertebral collapse and severe destruction, along with skeletal deformities and functional disability. In addition, compression of the spinal cord and/or nerve roots may result in neurologic deficits. Involvement of paravertebral soft tissues is a common feature of ST.

Materials and methods

Study design and data collection

The Backbone studies are two consecutive retrospective multinational/multicentre surveys. The Backbone-1 study compared brucellar and tuberculous SD patients, and its results will be published elsewhere. The Backbone-2 study, our focus here, included 314 patients with ST diagnosed and treated in 35 different centres between January 2000 and September 2013. The study period was the same in all of the centres involved in the study. Data of the patients were retrieved from hospital records and entered into a computer-based database designed for this study. The patients were followed for at least 6 months after termination of therapy. This study was approved ethically by the institutional review board of Dr Lutfi Kirdar Education and Research Hospital.

Inclusion criteria were as follows: patients with clinical and radiologic evidence of inflammation of one or more vertebrae and/or discitis plus microbiologic evidence and/or histopathologic evidence (caseating granulomas) of TB on bone, with or without paravertebral soft tissue specimen with or without other specimen rather than SD, and/or clinical and radiologic response to anti-TB therapy.

Microbiologic evidence included at least one of the following: isolation of *M. tuberculosis* in blood, bone, bone marrow, deep soft tissues and/or (paravertebral, epidural or psoas) abscess specimens; positive microscopy for acid-fast bacilli from bone, bone marrow, deep soft tissue and/or (paravertebral, epidural or psoas) abscess or any sterile body tissue (Ziehl–Neelsen

staining); positive rapid culture system results, such as BACTEC 460TB; or PCR for *M. tuberculosis* complex.

Imaging studies—magnetic resonance imaging (MRI), computed tomography (CT) or scintigraphy—were performed to define SD [12,13]. Radiologic criteria compatible with the diagnosis of ST included the following: hypointense signal on T1-weighted images; hyperintense signal on T2-weighted images; decreased height of intervertebral disc; osteolytic appearance of vertebral end plates; epidural involvement; paraspinal abscess with a thin and smooth abscess wall or rim enhancement; spread to three or more vertebral levels; involvement of multiple vertebral bodies; and mostly thoracic or lumbar spine involvement.

Exclusion criteria [6,14] included the following: age younger than 18 years; positive Wright standard agglutination test result; positive *Brucella* Coombs test result; enzyme-linked immunosorbent assay (ELISA) positive for *Brucella*; isolation of *Brucella* spp. from blood, bone, bone marrow, deep soft tissue and/or abscess (paravertebral, epidural or psoas) culture; and growth of pyogenic bacteria or fungi in the culture of the materials obtained from blood, bone, bone marrow, deep soft tissue and/or abscess material.

Definitions

VOM/SD was defined as the infection of the intervertebral disc and the adjacent vertebrae. Tuberculous SD/ST (TB) was defined as VOM caused by *M. tuberculosis* complex. Clinical cure was defined as resolution of all signs and symptoms of ST without any sequelae. Unfavourable outcome (UO) was defined as death or survival with sequelae or disability as irreversible neurologic or orthopaedic damage. We defined sequela as any morbid pathologic condition that is a consequence of ST, such as persistent pain, abnormal anatomic spinal findings (e.g. Gibbus deformity, scoliosis) or functional limitation, persisting for longer than 6 months after treatment. Neurologic deficit was defined as compromise/loss of sensory and/or motor neurologic function by compression of the spinal cord or nerve roots. Gibbus deformity was defined as a type of structural kyphosis of any vertebral level resulting from wedge-shaped vertebral bodies. Scoliosis was a form of deformity caused by curvature of the spine in the coronal plane. Kyphosis was posterior curvature of the thoracic spine beyond the normal physiologic limit in the sagittal plane.

Microbiologic tests

Microbiologic diagnosis was established with direct and indirect methods including the following.

Acid-fast bacilli. We tested for bacilli (e.g. *Mycobacteria*, *Nocardia*) that did not decolorize with acid–alcohol.

Acid-fast staining. Ziehl–Neelsen stain, Kinyoun stain or auramine–rhodamine stain were used to detect acid-fast bacilli.

Culture. Culture was the reference standard for the diagnosis of TB. However, 3–8 weeks were required for the growth of *Mycobacteria* in solid culture media (Lowenstein-Jensen, Middlebrook 7H11). Liquid broth cultures (Mycobacterial Growth Indicator Tube (MGIT) system, Middlebrook 7H12) showed organism growth in 1–3 weeks.

Nucleic acid amplification tests. These automated molecular tests included GeneXpert MTB/RIF real-time PCR assay (Cepheid, Sunnyvale, CA), Amplified *M. tuberculosis* Direct Test (Gen-Probe, San Diego, CA) and AMPLICOR *M. tuberculosis* Test (Roche Diagnostic Systems, Basel, Switzerland). Their sensitivity and specificity are nearly similar to those of culture.

Drug susceptibility tests. These tests included the agar proportion method, GeneXpert MTB/RIF assay, INNO-LiPA Rif. TB kit (Innogenetics, Zwijndrecht, Belgium) and Genotype MTBDRplus assay (Hain Life-science, Nehren, Germany).

Tuberculin skin test (TST). Five tuberculin units of purified protein derivative in 0.1 mL solution was injected intradermally, and the induration was measured 48–72 hours later. An induration more than 10 mm diameter in immunocompetent people corresponded to *M. tuberculosis* or latent TB infection. The QuantiFERON-TB Gold In-Tube Test (QFT-GIT), a type of interferon gamma release assay, was used to determine latent or active TB.

Statistical analyses

SPSS 17.0 (IBM, Armonk, NY) was used for statistical analysis. Categorical variables were presented as frequency and percentage, and continuous variables were presented as mean \pm standard deviation, and if not normally distributed as median (range). Chi-square or Fisher's exact test (two sided) was used for categorical variables. Student's *t* test or the Mann-Whitney *U* test was used for continuous variables, as appropriate. All variables associated with UO on univariate analysis with a *p* value of <0.2 were entered in a stepwise logistic regression analyses. The logistic regression model was internally validated with bootstrap analysis.

Results

Demographic and clinical features

A total of 314 patients (163 (52%) men) with ST from 35 different centres in four countries (Turkey, Egypt, Albania and Greece) were included. The mean age was 51 ± 18 years (range

18–91 years). Fifty-two (17%) of the patients' cohort and 21% of the subgroup with UO had another site of TB involvement (most commonly concomitant pulmonary TB). Comorbidities of the patients included diabetes mellitus ($n = 36$, 12%), chronic renal failure ($n = 14$, 5%), malignancy ($n = 7$, 2%), immunosuppression due to treatment with antineoplastic chemotherapy, glucocorticoids, TNF-alpha blockers ($n = 7$, 2%), and other (e.g. hypertension, coronary artery disease, chronic obstructive pulmonary disease, asthma, nephrolithiasis) ($n = 60$, 19%). Distribution of other sites of TB involvement is shown in Table 1.

The median duration from initial symptoms to the time of diagnosis was 78 days (range 2–1095 days). The majority of the patients experienced back pain (83%), and more than half experienced upper back pain (56%). The most common finding was tenderness over the involved area. Other signs and symptoms are listed in Table 1.

Laboratory findings

All of the patients were tested for anti-HIV by ELISA. None of the patients were infected with HIV. TST positivity was 75%. Median (range) erythrocyte sedimentation rate (ESR) and C-reactive protein (CRP) levels were 70 (4–159) mm/h and 30 (10–527) mg/L, respectively. Only 28% ($n = 88$) of the patients had leukocytosis ($>10\,000/\text{mm}^3$), while 2.5% had leucopenia ($<4000/\text{mm}^3$). Levels of other laboratory parameters were as follows: median white blood cell count (range): 8811 (945–34 960)/ mm^3 , median CRP (range): 30 (10–527) mg/L, median ESR (range): 70 (4–159) mm/h, mean hemoglobin: 11.5 ± 1.8 g/dL, mean platelet count: $292\,866 \pm 112\,376/\text{mm}^3$, median alanine aminotransferase (range): 23 (3–215) IU/L, median aspartate aminotransferase (range): 24 (2–194) IU/L, median lactate dehydrogenase (range): 237 (48–912) IU/L, median creatinine (range): 0.8 (0.2–9) mg/dL, mean serum protein: 7 ± 4.5 mg/dL, mean serum albumin: 3 ± 0.7 mg/dL.

Imaging data and level of vertebral involvement

Radiologic diagnosis was established by MRI in 92% ($n = 289$) of the patients. CT scanning and scintigraphy were performed in 118 (38%) and 26 (8%) of the patients. The mean number of involved vertebrae was 2.5 ± 1 vertebrae. Lumbar vertebrae (56%) were the most commonly involved region of the spinal column, followed by thoracic vertebrae (49%), but in the UO group, thoracic vertebral (58%) and lumbar involvements (57%) were similar. Although 51% of the patients (61% of the UO group) had adjacent multiple (>1 vertebra) levels of vertebral involvement, 8% had nonadjacent or noncontiguous involvement of multiple (>1 vertebra) vertebral bodies. Imaging findings of the patients with ST are provided in Table 2.

Microbiologic and histopathologic diagnosis

TST was performed in 210 patients (67%), with positive results in 158 (75%). The yield of diagnostic tests is demonstrated in Fig. 1. The aetiologic agent was isolated in 41% (75% from paravertebral abscess material) of the patients with samples that could be cultured, but an antimycobacterial susceptibility test was performed in only 21% ($n = 65$) of the isolates. Histopathologic examination (HPE) (most commonly of the paravertebral soft tissues (47%)) was performed in 200 patients (64%); 74% were inconsistent with TB. HPE was inconclusive in 19% ($n = 38$) of patients.

Neurologic compromise/complications

Pretreatment assessment of neurologic function and spinal stability revealed that the most common findings at baseline were abscess formation (69%) (with the majority paravertebral at 39%), neurologic deficits (40%), spinal instability (21%) and spinal deformity (16%). These findings were more commonly seen in patients who ultimately had UO with abscess formation in 74%, neurologic deficits in 56%, spinal instability in 36% and spinal deformity in 61% ($p < 0.05$). Complications that developed during the course of treatment were neurologic deficits (6%) and spinal deformities (4%). Data regarding complications are presented in Table 3.

Therapeutic features

Medical treatment alone was implemented in 103 patients (33%). A four-drug therapy including isoniazid (INH) + rifampin (RMP) + pyrazinamide (PZA) + ethambutol (EMB) and a four-drug regimen composed of INH + RMP + PZA + streptomycin (STM) were administered to 261 patients (83%) and 22 patients (7%) for the initial 2 months, respectively. Twenty-nine patients (9%) received initial five-drug (INH + RMP + PZA + EMB + STM) combination therapy. Antibiotic susceptibility testing was performed only in five of the patients receiving the five-drug regimen. After the initial four-drug regimen, most patients continued to receive a two-drug regimen with RMP and INH for a mean duration of 9 months. Adverse effects of anti-TB therapy were noted in only 57 patients (18%), as follows: nausea/vomiting, 22 (38.6%); hepatotoxicity, 17 (29.8%); rash, 5 (8.8%); leukopenia, 4 (7%); hearing problems, 3 (5.2%); fever, 2 (3.5%); significant hyperuricemia causing gouty arthritis or joint pain, 2 (3.5%); vertigo, 2 (3.5%); and blurred vision, 1 (1.8%). Adverse effects were assumed to be related to INH and RMP (17%), RMP (9%), PZA (7%), EMB (3%), STM (5%) and INH + RMP + PZA + EMB (6%). In 13 patients (4%), desensitization to drugs had been performed before the reinitiation of medical therapy. In 276 patients (88%), anti-TB therapy resulted in expected favourable outcomes. Treatment was modified in 25

TABLE 1. Demographic characteristics, clinical and laboratory features, imaging findings and complications of 314 patients with spinal TB

Characteristic	Favourable outcome	Unfavourable outcome ^a	p
Total	230	84	
Age (years)	50.7 ± 18	53.9 ± 18	0.06
Male sex	117 (51)	46 (55)	0.54
Other site of concomitant TB involvement	34 (15)	18 (21)	0.09
Pulmonary TB	13 (6)	10 (12)	
Pleural TB	3 (1)	3 (7)	
Mediastinal TB lymphadenitis	0	2 (2)	
TB meningitis	11 (5)	2 (2)	
Superficial TB lymphadenitis	4 (1)	0	
Gastrointestinal TB	1 (0.3)	0	
Peripheral joint TB	1 (0.4)	1 (1)	
Miliary TB	1 (0.3)	0	
Clinical findings/constitutional symptoms			
Fever	99 (43)	40 (48)	0.47
Fatigue	118 (51)	43 (51)	0.98
Loss of appetite	110 (48)	44 (52)	0.48
Sweating	112 (49)	40 (48)	0.87
Arthralgia	101 (44)	30 (36)	0.19
Lumbago/local tenderness	200 (87)	61 (73)	0.003
Back pain/local tenderness	127 (55)	49 (58)	0.62
Weight loss	98 (43)	34 (41)	0.79
Weight loss (kg)	8 ± 3	8 ± 3	0.37
Hepatomegaly (missing data in 9 patients)	30 (13)	11 (13)	0.96
Splenomegaly (missing data in 12 patients)	28 (12)	6 (7)	0.21
Imaging findings ^b			
Compatible with spondylodiscitis	215 (93)	83 (99)	0.06
Prevertebral abscess	25 (11)	12 (14)	0.40
Paravertebral abscess (missing data in 1 patient)	135 (59)	53 (63)	0.41
Epidural abscess (missing data in 1 patient)	35 (15)	19 (23)	0.11
Psoas abscess (missing data in 2 patients)	51 (22)	24 (29)	0.23
Radiculitis (missing data in 1 patient)	8 (3)	8 (10)	0.03
Neo-ossification (missing data in 1 patient)	10 (4)	9 (11)	0.03
Anterior involvement (missing data in 6 patients)	75 (33)	39 (46)	0.02
Multiple vertebral involvement (missing data in 6 patients)	108 (47)	51 (61)	0.04
Loss of vertebral corpus height	101 (44)	50 (60)	0.01
Calcification (missing data in 18 patients)	29 (13)	7 (8)	0.26
Instability (missing data in 18 patients)	29 (13)	28 (33)	<0.0001
Involved vertebrae			
Cervical	14 (6)	1 (1)	0.07
Cervicothoracic	3 (1)	0	
Thoracic	104 (45)	49 (58)	0.05
Thoracolumbar	24 (10)	16 (19)	0.85
Lumbar	127 (55)	48 (57)	0.86
Lumbosacral	18 (8)	6 (7)	0.40
Sacral	21 (9)	6 (7)	0.42
No. of involved vertebrae (missing data in 8 patients)	2 (1–8)	2 (1–6)	0.44
Multiple (>2 vertebrae) level involved (missing data in 7 patients)	72 (31)	34 (41)	0.15
Nonadjacent multiple-level involvement	14 (6)	12 (14)	0.04
Pretreatment complications			
Neurologic deficit	77 (33)	47 (56)	<0.0001
Loss of sensation	34 (15)	24 (29)	
Motor weakness	41 (18)	18 (21)	
Paralysis	2 (0.8)	5 (6)	
Spinal instability (missing data in 6 patients)	36 (16)	30 (36)	<0.0001
Spinal deformity	0	51 (61)	<0.0001
Abscesses	154 (67)	62 (74)	0.10
Paravertebral	77 (33)	46 (55)	
Epidural	8 (3)	13 (15)	
Psoas	46 (20)	14 (17)	
>1 abscess	19 (8)	17 (20)	
Peri- or posttreatment complications			
Neurologic deficit	0	20 (24)	<0.0001
Spinal instability	0	5 (6)	<0.0001
Spinal deformity	0	13 (16)	<0.0001
Abscesses	3 (1)	4 (5)	0.07

Data are presented as n (%), mean ± standard deviation or median (range).

TB, tuberculosis.

^aData were available as magnetic resonance imaging findings in 298 patients, as computed tomographic findings in 118 (38%) and as scintigraphic data in 26 (8%).

^bDefined as death or survival with any sequelae or disability despite therapy.

patients (8%) because of the adverse effects of the drugs (23.7%) and inadequate therapy (2, 0.6%).

A diagnostic and/or therapeutic surgical intervention was performed in 211 patients (67%); 37% received therapeutic surgery in addition to medical treatment. CT/ultrasound-guided percutaneous biopsy and/or abscess drainage (47%) was the most common diagnostic and therapeutic intervention

performed. Ten percent of the patients required more than one surgical intervention.

Outcome analysis

In univariate analysis, the number of the patients with advanced age (p 0.01), any malignant underlying disease (p 0.01), immunosuppression (p 0.01), neurologic deficit (p 0.004) and spinal

deformity ($p < 0.001$) were significantly higher in the UO group. In multivariate analysis, advanced age, presence of neurologic deficit and spinal deformity were the independent predictors of a UO (Table 4). Clinical cure was achieved in 230 patients (73.2%). Mortality occurred in 7 patients (2%); 77 (25%) developed any sequelae during or after treatment. The rates of posttreatment sequelae were as follows: 11% kyphosis, 6% Gibbus deformity, 5% scoliosis, 5% paraparesis, 5% paraplegia and 4% loss of sensation.

Discussion

In previously published Turkish studies on VOM, nearly one-third of the patients had ST [10,15,16]. In a large case series from Spain including 219 patients with VOM, ST constituted approximately one-fifth of the patients [5]. In the present study, the mean age of the patients, slightly over 50, was inconsistent with the previously published relevant literature in which most patients were younger than 40 [7,17]. Male subjects were slightly more predominant in our series, similar to the data reported in a recently published update on VOM [7]. Because back pain related to various causes is a common complaint in many patients, patients may not be referred to a hospital or seek medical care until symptoms get worse or the disease becomes progressive. Moreover, despite advanced diagnostic methods, diagnosis of ST is usually delayed: the median duration of symptoms before diagnosis has been reported to be between 2.5 and 6 months [5,7,15,18,19]. Median diagnostic delay in this study was 2.5 months, which was similar to the previous studies. In our study, more patients (7%) had concomitant active pulmonary TB compared to the previous largest case series report (2.7%) [17]. However, this is in contrast to another study from Turkey that reported disseminated TB in 19% of the patients with ST [10]. Less than half of the patients presented with fever in our series. Fever is a less common feature in ST, detected in only one-third of patients in other studies [5,7,18]. It should be taken into consideration that absence of fever in elderly patients with VOM may easily lead to misdiagnosis [19]. Constitutional symptoms were also present in nearly half of the patients. Lumbago and upper back pain were the most common presenting symptoms, similar to the findings reported by a majority of previous case series [13,18,20]. In contrast, a meta-analysis of the Turkish literature reviewing a large ST case series with a long follow-up period of 12 years by neurosurgeons and orthopedic surgeons documented that the most common presenting symptom was leg weakness, followed by Gibbus deformity. Only one-fifth of patients complained of pain initially [17]. However, in the present study, it was the other way round: leg weakness

occurred in only one-fifth of the patients, while pain was documented more frequently. The most probable reason for this discordance is referral bias in the meta-analysis study, as all the patients in that study were being followed by surgeons because they had neurologic deficits.

Rate of TST reactivity was 75% in this study. In a study on VOM reported from Turkey including 63 patients with ST, the sensitivity, specificity, positive predictive value and negative predictive value of TST were 66%, 97%, 89% and 88%, respectively [15]. TST and interferon gamma release assay tests are used in the diagnosis of latent TB infection, and their positive results do not confirm a diagnosis for active TB. Leukocyte counts have usually been reported to be in the normal range in ST [13]. In the present study, less than one-third of the patients had leukocytosis, while only 2.5% had leukopenia. However, ESR and CRP levels were usually elevated, similar to previous case series [21].

Plain radiographs play a role in diagnosis despite their low specificity—they are able to diagnose only half of the cases accurately [7,8,13]. MRI and CT are the most frequently preferred methods for diagnostic imaging [6,13,22]. CT is commonly used as a means of guidance for biopsy [7]. MRI in particular has a high sensitivity and specificity for early diagnosis of ST and is superior to other radiologic methods in revealing the extent of the disease and soft tissue involvement [6,7,13]. Therefore, radiologic diagnosis was established by MRI in the majority (92%) of our patients who had imaging findings compatible with ST in 95% of the cases [5]. However, spontaneous fusion of the vertebrae requires 12–24 months, and follow-up MRI may show radiologic progression despite clinical improvement of the patient [7]. Lower thoracic and upper lumbar vertebrae with soft tissue abscesses were reported to be involved in the majority of the patients with ST [5,7,15]. In this study, lumbar vertebrae were the most commonly involved site, followed by thoracic spine. However, in patients with UO, the disease affected thoracic vertebrae and lumbar vertebrae equivalently. Spinal deformity or instability may have been present at the time of diagnosis of ST [5]. Our results are consistent with those of previous studies, as more than half of our patients with UO had spinal deformity at the time of diagnosis. Spinal instability was seen in one-third of our patients with UO. Multiple segment (>1 vertebra) involvement has been reported to be a feature of ST [7]. In agreement with these updated data, in one-third of our patients, multiple (>1) vertebrae were affected, in contrast to some other studies (2.4–3%) [5,10]. The authors of those reports may have referred to nonadjacent or noncontiguous involvement of multiple vertebral bodies as multiple segment involvement because the definition of “multiple” is not clear in those studies. Paraspinal, epidural and/or paravertebral abscesses were

TABLE 2. Results of microbiologic and histopathologic diagnostic tests for tuberculous spondylodiscitis

Characteristic	n (%)
Positive culture	110/271 (41)
Culture specimen	
Blood culture	2 (0.6)
Bone biopsy culture	12 (4)
Bone marrow culture	1 (0.3)
Deep soft tissue culture	16 (5.1)
Abscess material culture	78 (25)
Paravertebral abscess	54 (17)
Epidural abscess	5 (1.6)
Psoas abscess	21 (6.7)
Lymph node culture	1 (0.3)
Identification of <i>Mycobacteria</i>	
<i>Mycobacterium tuberculosis</i> complex	59 (54)
<i>M. tuberculosis</i>	49 (45)
Antimicrobial susceptibility test performed	3 (1)
HPE performed	200
Compatible with TB	147 (74)
Nonspecific findings	38 (19)
Insufficient material	15 (7)
Site of HPE	
Bone	52 (26)
Paravertebral soft tissue	94 (47)
Bone and paravertebral soft tissue	15 (8)
Other foci	36 (18)
Vertebral level material for HPE obtained	
Cervical	7 (4)
Thoracic	82 (41)
Lumbar	76 (38)
Sacral	1 (0.5)

HPE, histopathologic examination; TB, tuberculosis.

reported in the majority of our patients with ST, with rates similar to those of previous studies [5,10,18,21,23]. In contrast to previous case series [17], more of our patients (8%) had nonadjacent or noncontiguous involvement of multiple vertebral bodies.

Number of patients

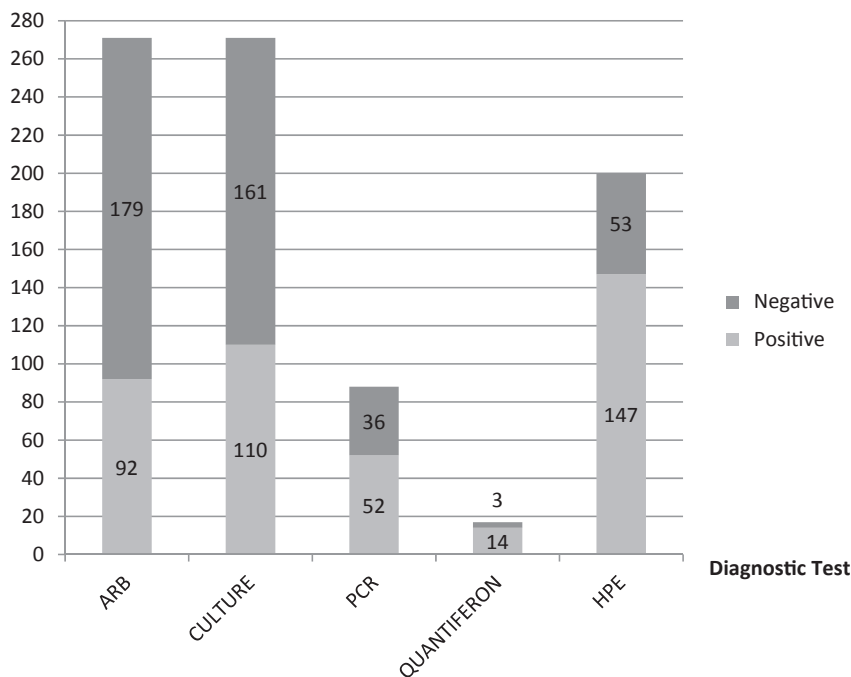


FIG. 1. Yield of different diagnostic procedures. ARB, acid-fast bacteria; PCR, polymerase chain reaction; HPE, histopathologic examination.

Neurologic compromise may occur as a result of cord compression by a large abscess, particularly in cases with delayed diagnosis [7,11]. Neurologic symptoms and/or spinal cord compression have been reported to be between 16% and 69% in various studies [5,7,10,17,18,21,23]. In our series, pre-treatment presence of neurologic deficit was present in more than half of the patients with UO. Kyphosis and Gibbus deformity have been reported to be common spinal deformities in ST [7]. In the present study, both types of deformities were the most common deformities detected in patients with UO. Because they may require surgical intervention, close monitoring of the neurologic status of the patient is necessary [22].

For the definitive diagnosis of ST, microbiologic and/or histopathologic analyses are necessary [6]. Previous publications indicate that most surgeons and radiologists rely on microbiologic diagnosis. However, other physicians, including infectious diseases specialists and pathologists, are aware that these techniques may fail to diagnose ST [13]. Histopathologic diagnosis (64%) outweighed microbiologic diagnosis (41%) in our case series. Sensitivity of cultures to detect the causative agent has been reported to be 80% [24]. Negative microbiologic results should not exclude the diagnosis [13]. Nevertheless, isolation of *Mycobacteria* is crucial to proceed to susceptibility tests [24]. Percutaneous biopsy should be performed in any patient with a clinical picture suggestive of VOM before initiation of therapy [18]. Because it is sometimes difficult to convince patients to undergo a biopsy, and because

TABLE 3. Treatment and outcome of 314 patients with spinal tuberculosis

Treatment	Value
Treatment	
INH, RIF, PRZ, EMB	261 (83)
INH, RIF, PRZ, STM	22 (7)
INH, RIF, PRZ, EMB, STM	29 (9)
Corticosteroid therapy	13 (4)
Missing data	2 (1)
Duration of therapy (months)	11.6 ± 2.5
Surgical intervention	211 (67)
Percutaneous biopsy with or without abscess drainage	100 (47)
Open abscess drainage	34 (16)
Transpedicular stabilization and fusion	23 (11)
Multiple surgical interventions	22 (10)
Laminectomy	13 (6)
Drainage and intermittent irrigation	7 (3)
Corpectomy and stabilization	1 (0.4)
Diskectomy	1 (0.4)
Reason for surgical intervention	
Diagnostic	49 (23)
Diagnostic and therapeutic	68 (32)
Therapeutic	78 (37)
Any surgical complication	2 (0.9)
Reasons for surgical intervention	
Pain	57 (27)
Neurologic deficit	24 (11)
Not documented	130 (62)
Response to treatment	
Clinical (fever, pain relief) cure	230 (73)
Laboratory improvement	242 (77)
CRP normalization	246 (78)
Time to CRP normalization (days)	16 (70, 7)
ESR normalization	198 (63)
Time to ESR normalization	28 (120, 30)
Follow-up imaging results	
Cure	48 (15)
Radiologic improvement	137 (44)
Worsening of radiologic findings	13 (4)
Unfavourable outcomes	84 (27)
Mortality	7 (2)
Posttreatment sequelae ^a	77 (25)
Kyphosis	35 (11)
Gibbus deformity	18 (6)
Motor weakness	17 (5)
Paraplegia	17 (5)
Scoliosis	15 (5)
Loss of sensation	12 (4)
Kyphoscoliosis	3 (1)
Vertebral compression fracture	2 (0.6)
Persistent pain	2 (0.6)
Urinary retention	1 (0.3)
Polyneuropathy	1 (0.3)

Data are presented as *n* (%), mean ± standard deviation or median (interquartile range).
 CRP, C-reactive protein; EMB, ethambutol; ESR, erythrocyte sedimentation rate; INH, isoniazid; PRZ, pyrazinamide; RIF, rifampin; STM, streptomycin.
^aNumber of diagnoses, not patients.

experienced radiodiagnostic specialists are needed to perform CT/ultrasound-guided biopsy, HPE could only be done in 64% of our cases, three-fourths of the findings of which were compatible with TB. In another study, invasive procedures (e.g. bone biopsy) for diagnosis were performed in three-fourths of patients with ST [21]. In 66–90% of patients who underwent biopsy, the diagnosis of ST was established microbiologically and/or histopathologically [10,24]. Culture results have been reported to reveal the causative pathogen in up to half of percutaneous biopsies and in more than half of open biopsies. After histologic findings were evaluated together with microbiologic results, the diagnostic yield of percutaneous biopsies has been known to increase [18,23]. Molecular methods like

PCR may help in diagnosis of culture-negative cases and may prevent misdiagnosing ST as pyogenic VOM. Particularly, PCR offers an alternative means of diagnosis in patients who received antibiotics previously and those who were infected with fastidious-growing microorganisms [25]. PCR may also have false-negative or false-positive results as a result of contamination [13,25].

Multidrug regimens starting with four drugs and continuing with two more are recommended for treatment of TB. In the past, longer courses (12–18 months) of anti-TB therapy had been recommended for ST. However, later it was demonstrated that 6 to 9 months of regimens including RMP were as effective as longer-duration regimens [26]. In the case of advanced disease with complications, or if RMP cannot be included in the regimen for whatever reason, treatment duration may have to be lengthened [27]. In the present study, mean duration of therapy was nearly 1 year (11.6 months). One-third of our patients received medical treatment alone. Conservative medical treatment in patients without neurologic symptoms or spinal deformities resulted in clinically successful therapeutic responses in 95% of the patients [23]. Surgical intervention is necessary to obtain specimens for diagnostic purposes when percutaneous aspiration fails to disclose the aetiology, or when neurologic deficits, spinal instability, kyphosis of >40 degrees and cold abscess are present [11,28,29]. The rate of necessity for surgical intervention is higher in ST compared to VOM caused by other pathogens [5,21,22]. The need for urgent decompression is the main reason for emergency surgery in patients with neurologic symptoms. In a meta-analysis including surgical patients with ST, the causes of surgery were documented as follows: spinal deformity in 59%, neurologic deficits in 38%, intractable pain in 3% and abscess enlargement unresponsive to medications in 3% [17]. In our study, 67% of patients required surgical intervention, and 67% of them were for therapeutic purposes. In other studies that included fewer patients with neurologic deficits or deformity, the rate of surgery was accordingly low [10].

Mortality occurred in 7 patients (2%); the mortality rate was the same as that reported in a meta-analysis from Turkey [17]. Seventy-seven patients (25%) developed any sequelae, such as kyphosis, Gibbus deformity, scoliosis, paraparesis, paraplegia and loss of sensation, in descending order. Patients with advanced age, malignant underlying diseases, immunosuppression, neurologic deficit and spinal deformity had more UO. Advanced age, presence of neurologic deficit and spinal deformity were independent predictors of a UO and also accounted for the indications for surgery [22]. Although the rates of neurologic deficits before therapy and surgical intervention in the present study were similar to those reported by Colmenero *et al.* [18], the number of patients with severe functional sequela was much lower (25%) than the number of patients in

TABLE 4. Comparison characteristics of patient with spinal tuberculosis for favourable and unfavourable outcomes

Characteristic	Univariate analysis			Multivariate analysis	
	Favourable outcome (n = 230)	Unfavourable outcome (n = 84)	p	Adjusted OR (95% CI)	p
Age (years)	49 ± 18	56 ± 16	0.013	1.02 (1.0–1.04)	0.030
Female sex	122 (48.2)	29 (47.5)	0.92	—	—
Diabetes mellitus	29 (11.5)	7 (11.5)	1.00	—	—
Chronic renal disease	11 (4.3)	3 (4.9)	0.85	—	—
Malignant underlying disease	3 (1.2)	4 (6.6)	0.01	3.09 (0.51–18.65)	0.22
Immunosuppression	3 (1.2)	4 (6.6)	0.001	3.52 (0.68–18.37)	0.14
Neurologic deficit	79 (31.2)	31 (50.8)	0.004	1.93 (1.03–3.61)	0.041
Spinal instability	51 (20.2)	15 (24.6)	0.45	—	—
Abscess formation	169 (66.8)	45 (73.8)	0.29	—	—
Spinal deformity	21 (8.3)	23 (37.7)	<0.001	5.42 (2.65–11.09)	<0.0001
Duration of symptoms before diagnosis (days)	149 ± 187 (n = 250)	193 ± 227 (n = 61)	0.11	1.00 (1.0–1.0)	0.086

Data are presented as mean ± standard deviation or n (%).
CI, confidence interval; OR, odds ratio.

that study (39%). Among patients who were treated surgically in addition to medical anti-TB therapy, only 9% were reported to have experienced deterioration after treatment [17]. All the others improved or remained stable.

There were some limitations of our study. Because all the contributors of this study are infectious diseases clinicians, we could not assess the details of surgical procedures and their outcomes. Furthermore, because the study was retrospective in nature, we were also limited by the data available in the medical records.

In conclusion, ST results in a significant rate of morbidity as a result of its insidious course and delayed diagnosis. Patients with complications already present before the initiation of treatment were more likely to develop neurologic sequelae. Advanced age, presence of any neurologic deficit and spinal deformity were predictors of UO in this study. ST should be considered in the differential diagnosis of patients with VOM, especially in TB-endemic regions. Early establishment of definitive aetiological diagnosis and appropriate treatment are of paramount importance to prevent development of sequelae.

Transparency declaration

All authors report no conflicts of interest relevant to this article.

References

- [1] Fitzgerald DW, Sterling TR, Haas DW. *Mycobacterium tuberculosis*. In: Mandell GL, Bennett JE, Dolin R, editors. *Mandell, Douglas, and Bennett's principles and practice of infectious diseases*. 8th ed. Philadelphia: Churchill Livingstone; 2015. p. 2787–818.
- [2] Erdem H, Akova M. Leading infectious diseases problems in Turkey. *Clin Microbiol Infect* 2012;18:1056–67.
- [3] World Health Organization. *Global tuberculosis report*. Geneva: WHO; 2012.
- [4] Peto HM, Pratt RH, Harrington TA, LoBue PA, Armstrong LR. Epidemiology of extrapulmonary tuberculosis in the United States, 1993–2006. *Clin Infect Dis* 2009;49:1350–7.
- [5] Colmenero JD, Jimenez-Mejias ME, Sanchez-Lora FJ, et al. Pyogenic, tuberculous, and brucellar vertebral osteomyelitis: a descriptive and comparative study of 219 cases. *Ann Rheum Dis* 1997;56:709–15.
- [6] Berbari EF, Steckelberg JM, Osmon DR. Vertebral osteomyelitis and spondylodiskitis. In: Mandell GL, Bennett JE, Dolin R, editors. *Mandell, Douglas, and Bennett's principles and practice of infectious diseases*. 8th ed. Philadelphia: Churchill Livingstone; 2015. p. 1322–3.
- [7] Gouliouris T, Aliyu SH, Brown NM. Spondylodiscitis: update on diagnosis and management. *J Antimicrob Chemother* 2010;65(Suppl. 3):iii11–24.
- [8] Shikhare SN, Singh DR, Shimpi TR, Peh WC. Tuberculous osteomyelitis and spondylodiscitis. *Semin Musculoskelet Radiol* 2011;15:446–58.
- [9] McHenry MC, Easley KA, Locker GA. Vertebral osteomyelitis: long-term outcome for 253 patients from 7 Cleveland-area hospitals. *Clin Infect Dis* 2002;34:1342–50.
- [10] Mete B, Kurt C, Yilmaz MH, et al. Vertebral osteomyelitis: eight years' experience of 100 cases. *Rheumatol Int* 2012;32:3591–7.
- [11] Trecarichi EM, Di Meco E, Mazzotta V, Fantoni M. Tuberculous spondylodiscitis: epidemiology, clinical features, treatment, and outcome. *Eur Rev Med Pharmacol Sci* 2012;16(Suppl. 2):58–72.
- [12] Jung NY, Jee WH, Ha KY, Park CK, Byun JY. Discrimination of tuberculous spondylitis from pyogenic spondylitis on MRI. *AJR Am J Roentgenol* 2004;182:1405–10.
- [13] Wang D. Diagnosis of tuberculous vertebral osteomyelitis (TVO) in a developed country and literature review. *Spinal Cord* 2005;43:531–42.
- [14] Ulu-Kilic A, Karakas A, Erdem H, et al. Update on treatment options for spinal brucellosis. *Clin Microbiol Infect* 2014;20:O75–82.
- [15] Eren Gok S, Kaptanoglu E, Celikbas A, et al. Vertebral osteomyelitis: clinical features and diagnosis. *Clin Microbiol Infect* 2014;20:1055–60.
- [16] Yasar K, Pehlivanoglu F, Cicek G, Sengoz G. The evaluation of the clinical, laboratory and the radiological findings of the fifty-five cases diagnosed with tuberculous, brucellar and pyogenic spondylodiscitis. *J Neurosci Rural Pract* 2012;3:17–20.
- [17] Turgut M. Spinal tuberculosis (Pott's disease): its clinical presentation, surgical management, and outcome. A survey study on 694 patients. *Neurosurg Rev* 2001;24:8–13.
- [18] Colmenero JD, Jimenez-Mejias ME, Reguera JM, et al. Tuberculous vertebral osteomyelitis in the new millennium: still a diagnostic and therapeutic challenge. *Eur J Clin Microbiol Infect Dis* 2004;23:477–83.

- [19] Buranapanitkit B, Lim A, Geater A. Misdiagnosis in vertebral osteomyelitis: problems and factors. *J Med Assoc Thai* 2001;84:1743–50.
- [20] Fuentes Ferrer M, Gutierrez Torres L, Ayala Ramirez O, Rumayor Zarzuelo M, del Prado Gonzalez N. Tuberculosis of the spine. A systematic review of case series. *Int Orthop* 2012;36:221–31.
- [21] Turunc T, Demiroglu YZ, Uncu H, Colakoglu S, Arslan H. A comparative analysis of tuberculous, brucellar and pyogenic spondylodiscitis patients. *J Infect* 2007;55:158–63.
- [22] Guerado E, Cervan AM. Surgical treatment of spondylodiscitis. An update. *Int Orthop* 2012;36:413–20.
- [23] Kotil K, Alan MS, Bilge T. Medical management of pott disease in the thoracic and lumbar spine: a prospective clinical study. *J Neurosurg Spine* 2007;6:222–8.
- [24] Colmenero JD, Ruiz-Mesa JD, Sanjuan-Jimenez R, Sobrino B, Morata P. Establishing the diagnosis of tuberculous vertebral osteomyelitis. *Eur Spine J* 2013;22(Suppl. 4):579–86.
- [25] Fenollar F, Levy PY, Raoult D. Usefulness of broad-range PCR for the diagnosis of osteoarticular infections. *Curr Opin Rheumatol* 2008;20:463–70.
- [26] Five-year assessment of controlled trials of short-course chemotherapy regimens of 6, 9 or 18 months' duration for spinal tuberculosis in patients ambulatory from the start or undergoing radical surgery. Fourteenth report of the Medical Research Council Working Party on Tuberculosis of the Spine. *Int Orthop* 1999;23:73–81.
- [27] Blumberg HM, Leonard Jr MK, Jasmer RM. Update on the treatment of tuberculosis and latent tuberculosis infection. *JAMA* 2005;293:2776–84.
- [28] Tuli SM. Tuberculosis of the spine: a historical review. *Clin Orthop Relat Res* 2007;460:29–38.
- [29] Pola E, Rossi B, Nasto LA, Colangelo D, Logroscino CA. Surgical treatment of tuberculous spondylodiscitis. *Eur Rev Med Pharmacol Sci* 2012;16(Suppl. 2):79–85.